

Effect of ozonated olive oil on experimentally induced skin infection by *Streptococcus pyogenes* and *Staphylococcus aureus* in rats

Kemal Varol^{1*}, Fatih Mehmet Birdane² & Ihsan Keles¹

¹Department of Internal Medicine, Faculty of Veterinary Medicine, University of Erciyes, Kayseri-38100 Turkey

²Department of Internal Medicine, Faculty of Veterinary Medicine, University of Afyon Kocatepe, Afyonkarahisar-03200, Turkey

Received 09 May 2016; revised 04 June 2017

Antibiotic resistance problem is one of the most important problems in treating infectious diseases. To overcome such problems, agents apart from antibiotics that can be used in the treatment of infectious diseases and have no resistance problem should be explored. Natural substances, such as vegetable oils and ozone are possible resources. Thus, in the present study, we investigated the effect of ozonated olive oil on experimentally induced skin infection by *Streptococcus pyogenes* and *Staphylococcus aureus* in rats. The study was performed on 3 main groups. Experimental skin infection was induced by *S. pyogenes* (Group 1) or *S. aureus* (Group 2). Animals in Groups 1.1 (n=10) and 2.1 (n=10) received ozonated olive oil, in Groups 1.2 (n=10) and 2.2 (n=10) received olive oil, in Groups 1.3 (n=10) and 2.3 (n=10) received fusidic acid on the infection side in their skin at 24, 28, 32, 40, 48, 56, 64, 72, 80, 88, 96 hours. Groups 1.4 (n=11) and 2.4 (n=11) did not receive any treatment after infection. Group 3 (n=11) received only serum physiologic at above mentioned periods. After occurrence of the skin infection; ozonated olive oil had anti-microbial, anti-inflammatory effects and observed to have healing activity at 72-80 h after infection. Furthermore, the effects of ozonated olive oil were comparable with the effects of fusidic acid which its activity proved against skin infections with *Staphylococcus* and *Streptococcus*.

Keywords: Fusidic acid, Olive oil, Ozonated oil, Ozone, Ozone therapy

Staphylococci and *Streptococci* are gram positive and cocci morphology bacteria¹. *Streptococcus pyogenes* and *Staphylococcus aureus* are the most commonly encountered microorganisms of bacterial infections of the skin in humans². Though in animals too *S. aureus* causes bacterial infections of the skin mostly, at times *S. pyogenes* also leads to mono infection of skin³. In the treatment of skin infections caused by bacteria, both systemic and local treatment can be applied⁴. Overuse, low dose or ineffective duration of antibiotics usage in the treatment of infectious diseases cause resistance⁵. Ozone therapy has come up as an alternative treatment option that does not cause any such resistance⁶⁻¹¹.

Ozone is a natural gaseous molecule consists of three oxygen atoms whereas the oxygen molecule, far more stable and is composed of only two atoms¹². Ozone has a strong germicidal activity and destroys bacterial cell membrane integrity by the oxidation of phospholipids and lipoproteins. It can break down the cell wall of many pathogenic microorganisms^{5,13}. Ozone, has been used as the oxygen-ozone mixture,

ozonated oil and ozonated water in bacterial skin infections in human^{12,14-16}.

However, effects of ozonated olive oil (OZO) on experimentally induced skin infection by *S. aureus* and *S. pyogenes* in rats have not been reported in literature until now. In the present study, we evaluated the potential effect and antibacterial activity of OZO on experimentally induced skin infection using *Streptococcus pyogenes* and *Staphylococcus aureus* in rats.

Materials and Methods

Nintey-three female Wister Albino rats aged between 6 and 8 weeks weighing 80-130 g were grouped into 3 main groups wherein Group 1 was infected with *Streptococcus pyogenes*; Group 2 was infected with *Staphylococcus aureus*; and Group III was negative control group. Infections were made in the skin of the experimental animals as described by Kugelberg *et al.*¹⁷ with some modifications described below. Furthermore, each of Group 1 & 2 were further divided into 4 subgroups.

The animals used in the present study were obtained from the Laboratory Animal Research Centre of the University of Erciyes. Experiment,

*Correspondence:
E-mail: kmlvrl@yahoo.com

hosting and maintenance were made at this centre. Ethical Commity Permission were taken from the Ethical Committee of the Local Animal Experiment Commission, University of Afyon Kocatepe as the 420-15 Reference number and dated on 12.02.2015 with the 4953302/09 number.

Apart from *S. pyogenes* or *S. aureus* infection, animals in Groups 1.1 (n=10) and 2.1 (n=10) received 0.1 g. OZO; Groups 1.2 (n=10) and 2.2 (n=10) received olive oil (OL); and Groups 1.3 (n=10) and 2.3 (n=10) received 0.1 g fusidic acid (FA) on the infection side of the skin at 24, 28, 32, 40, 48, 56, 64, 72, 80, 88, 96 h. Groups 1.4 (n=11) and 2.4 (n=11) did not receive any treatment after infection. Group 3 (n=11) received only 0.1 g serum physiologic at above mentioned periods.

Experimental skin infection

Infection, modified from Kugelberg *et al.*¹⁷ superficial skin infection model. Under general anaesthesia (xazine 10 mg/kg; basilazin 2% bavet, ketamine 50 mg/kg; ketasol 10%, interhas), first hairs were shaved by fixing the epilating strip and then removing it quickly. It was repeated three times. Abraded skin regions were obtained and the area was disinfected with a disinfectant (baticon) and alcohol. Before inoculation of bacteria, swaps were taken from the abraded skin and were kept at +4°C for microbiological analysis. The Wattman paper (11 millimeter in diameter) was placed on to the abraded skin region. Standard strains of *S. aureus* ATCC 25923 and *S. pyogenes*, a clinical isolates, were obtained from the Erciyes University, Medical Faculty, Microbiology Laboratory. About 0.1 mL of *S. pyogenes* strain and *S. aureus* ATCC 25923 strain (each 1×10^8 CFU/mL) was prepared and were adsorbed on to the Wattman paper. After the bacterial inoculation, the infection area was covered with an adhesive bandage (Betafix) and closed with adhesive tape to protect animals from removing the adhesive bandage. Bandage and strip were removed after 24 h of infection. To determine the status of infection, swaps were taken from the region before the treatment. Then, treatment was started and continued up to 96 h. Clinical finding scores were made for recovery as 1 (No), 2 (Low), 3 (moderate) and 4 (severe).

Histopathological analysis

Tissue samples under general anaesthesia using 4 mm biopsy punch before treatment and 24, 28, 32, 40, 48, 56, 64, 72, 80, 88, 96 h after the treatment were collected and evaluated in all groups. The biopsy

samples fixed in formalin (10%). The formalin-fixed biopsy specimens were embedded in paraffin and stained with haematoxylin (Sigma-HHS32-1L) and eosin (Merck-109844.1000). For identification of the bacteria, the biopsy specimens were gram's stained (Merck-M111885.0001). Furthermore, swap samples before treatment and only 24 h after treatment were collected to determine the presence of infection in all groups.

Ozonation procedure and Characterization of oils

As required for experimental study, OL and OZO material was obtained from a certified commercial company (Aktifoks, Isık Cosmetics/Turkey). According to the commercial firm Hansler brands (Ozonosan Alpha Plus, Germany), the ozone device (which produce 95% oxygen and 5% ozone mixture) was used to prepare 10 L of OL which this device reported to produce 25 mg/L of ozone per min in the 18-20°C. This procedure was applied for 10 days. Acidity, peroxide, iodine and p-anisidine values of OL and OZO were determined according to AOCS¹⁸, AOCS¹⁹, AOCS²⁰, AOCS²¹ respectively. The pH value of OL and OZO were determined at room temperature (24°C). Viscosity of OL and OZO were determined by vibrating viscometer device (AND SV-10 Japan) at 24-40°C. These values are important for obtaining a high quality OZO^{22,23}.

Fusidic acid and stafine cream material

This material obtained from a commercial firm (Kocak Farma AS/Turkey) which is licensed for human use as local application and can be obtained from any chemist shop. In the animal experiment, stafine cream was used.

Determination of antimicrobial activity

The antimicrobial activity was determined by antimicrobial disc diffusion tests with FA, OZO and OL according to the CLSI²⁴ and CLSI²⁵ methods, respectively.

Statistical analysis

The IBM SPSS 21 for Windows software statistical package program was used for statistical analysis. Statistical comparisons with concern to clinical findings in between groups and within group were made using Kruskal-Wallis test. Statistical comparisons of presence of bacteria in between groups were made using Chi-square test. Values were given as mean \pm standard deviation. The level of $P < 0.05$ was used to determine the significance.

Results

Antimicrobial sensitivity and disc diffusion tests are given in Table 1. According to the table both microorganisms used in the present study were resistant against OL but not against FA and OZO (Table 1).

After preparing the animals for infection, swaps were taken before and 24 h after infection. Swaps taken before infection (Groups 1, 2 and 3), inoculated for microbiological analysis. No bacterial growth was observed in any of the groups. However, bacterial growth developed in the swaps taken after 24 h of infection in all the infected samples (Fig. 1 B & C, Fig. 2 B & C, and Fig. 3 B & L).

Presence of bacteria in the dermis in Groups 1, 2 and 3 were given in Table 2 and 3. According to this table, Group 3 which was negative control and it had no bacterial growth. In Groups 1.4 and 2.4, bacterial growth were 100% which were positive controls. The least bacterial growth in dermis were in Groups 1.1, 2.3, 1.3, 2.1, 1.2 and 2.2, respectively (Table 2 and 3), (Fig. 1 B & C, Fig. 2 B & C).

Table 1—*Staphylococcus aureus* ATCC 25923 and *Streptococcus pyogenes* (a clinical isolate) antimicrobial sensitivity tests results

Strain	Fucidic acid			Ozonated olive oil		Olive oil	
	5 µg disc (mm)	10 µg disc (mm)	MICs (µg/mL)	Disc (mm)	MICs (µg/mL)	Disc (mm)	MICs (µg/mL)
<i>S. aureus</i> ATCC 25923	25	26	0.25	10	0.25	Resistant	Resistant
<i>S. pyogenes</i> clinical isolate	30	40	0.03	16	0.25	Resistant	Resistant

[(MICs) Minimum inhibitory concentration]

Table 2—Presence of bacteria in dermis (%), presence of inflammatory cells [neutrophil and mononuclear cell infiltration (%)] in papillary dermis, reticular dermis and subcutis in Groups 1 and 3

Groups 1 and 3	Bacteria	Papillary dermis	Reticular dermis	Subcutis
G. 1. 1 (n=10)	18.2 ^{ab}	18.2 ^{ab}	9.1 ^a	27.3 ^{ab}
G. 1. 2 (n=10)	63.6 ^{bc}	63.6 ^{bc}	27.3 ^a	27.3 ^b
G. 1. 3 (n=10)	36.4 ^{ab}	45.5 ^{ab}	45.5 ^{ab}	60.0 ^{bc}
G. 1. 4 (n=11)	100.0 ^c	100.0 ^c	100.0 ^{ab}	100.0 ^c
G. 3 (n=11)	0.0 ^a	0.0 ^a	0.0 ^a	0.0 ^a
<i>p</i>	<0.001	<0.001	<0.001	<0.001

[Different letters in the same column determine statistical significance (P <0.05)]

Inflammatory cell ratios in papillary dermis, reticular dermis and subcutis are given in Table 2 and 3. According to these tables, no inflammatory cells were observed in Group 3 histopathologically. Inflammatory cell ratios in Groups 1.4 and 2.4 were

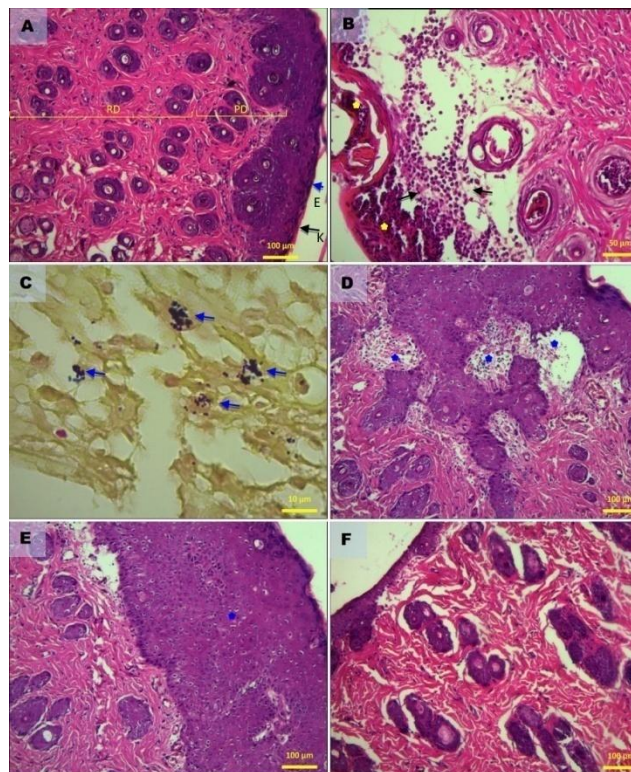


Fig. 1—Histopathological findings Group 1 and Group 3. (A) Negative control (Group 3), normal skin histology. Hematoxylin-eosin (HXE); (B-C): infected control group (Group 1.4.), [(B) Subcorneal pustules (stars), intensive mononuclear cell infiltration (arrows). (72nd h), (C) Gram stain. Subcutaneous tissue in the lumen of the coccoid bacteria clusters (24 h)]; and (D-F): Treatment Group, (D) Olive oil treated group (Group 1.2), intense mononuclear cell infiltration is still severe (Blue stars) (72nd h), (E) Fucidic acid treated group (Group 1.3), (72nd h); it disappeared inflammatory reaction in the dermis but still hyperplastic epithelium (Blue stars), (F) Ozonated olive oil group (Group 1.1), (72nd h), healing, the epithelium and dermis, normal view available. Bar x10 (A,D,E,F) x 40 (B) x 100 (C).

Table 3—Presence of bacteria in dermis (%), presence of inflammatory cells [neutrophil and mononuclear cell infiltration (%)] in papillary dermis, reticular dermis and subcutis in Groups 2 and 3

Groups	Bacteria	Papillary dermis	Reticular dermis	Subcutis
G. 2. 1 (n=10)	45.5 ^{ab}	18.2 ^{ab}	20 ^{ab}	63.6 ^{bc}
G. 2. 2 (n=10)	81.8 ^{bc}	45.5 ^{ab}	46.4 ^{ab}	36.4 ^{abc}
G. 2. 3 (n=10)	27.3 ^{ab}	9.1 ^a	45.5 ^{bc}	18.2 ^{ac}
G. 2. 4 (n=11)	100.0 ^c	72.7 ^b	100.0 ^c	90.9 ^b
G. 3. (n=11)	0.0 ^a	0.0 ^a	0.0 ^a	0.0 ^a
<i>p</i>	<0.001	<0.001	<0.001	<0.001

[Different letters in the same column determine statistical significance (P <0.05)]

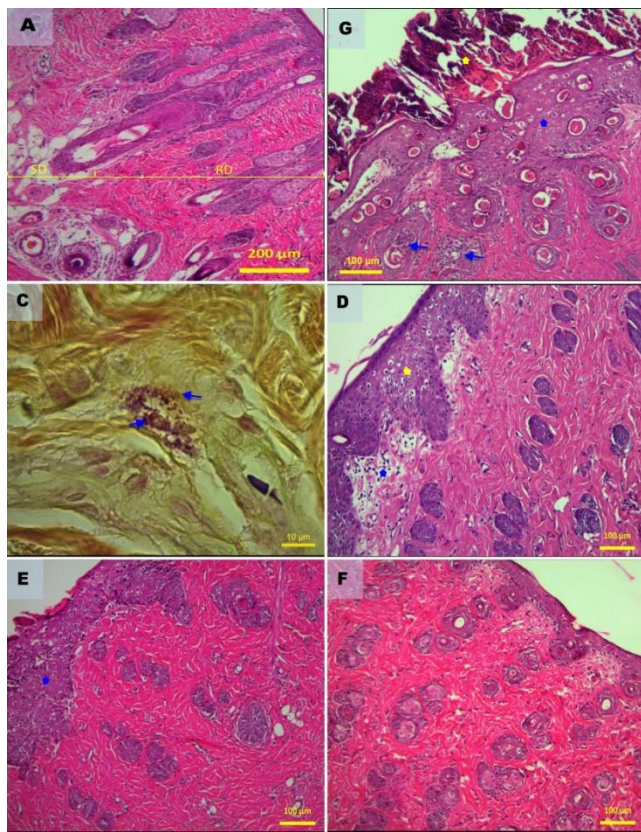


Fig. 2—Histopathological findings Group 2 and Group 3. (A) Negative control group (Group 3), normal skin histology, hematoxylin-eosin (HXE) (24th h); (B-C): infected control group (Group 2.4), (B) Subcorneal pustules (Blue star), intensive mononuclear cell infiltration (Yellow star), (80th h), (C) Gram stain. Subcutaneous tissue in the lumen of the coccoid bacteria clusters (24th h); and (D-F): Treatment group, (D) Olive Oil group (Group 2.2). Epidermal acanthosis, vacuolization in spinosa cells and intensive mononuclear cell infiltration is still severe (Blue star) edema in papillary dermis (Yellow star), (80th h), (E) Fucidic acid treated group (Group 2.3), (80th h), disappeared inflammatory reaction in the dermis but vacuolization in spinosa cells, hyperplasias (blue star) still present, (F) Ozonated olive oil treated group (Group 2.1), (80th h); epithelium and dermis normal view Bar x10 (A,D,E,F) x 40 (B) x 100 (C).

the highest which were infected controls. The lowest inflammatory responses were in the other groups (Fig. 1B and Fig. 2B).

Treatments started 24 h after infections in all groups. Healing started Group 1.1 and Group 2.1 at 40 h (Fig. 3 E & M). Healing completed in Group 1.1 at 72th h (Fig. 1 F & F), in Group 2.1, Group 1.3 and Group 2.3 at 80 h (Fig. 1E, Fig. 2 E & F, Fig. 3 J, P & T). In Groups 1.2, Groups 2.2, Groups 1.4 and Groups 2.4, the healing process did not occur up to 80 h (Fig. 1 B & D, Fig. 2 B & D, Fig. 3 D, H, N & R), (Tables 4 and 5).

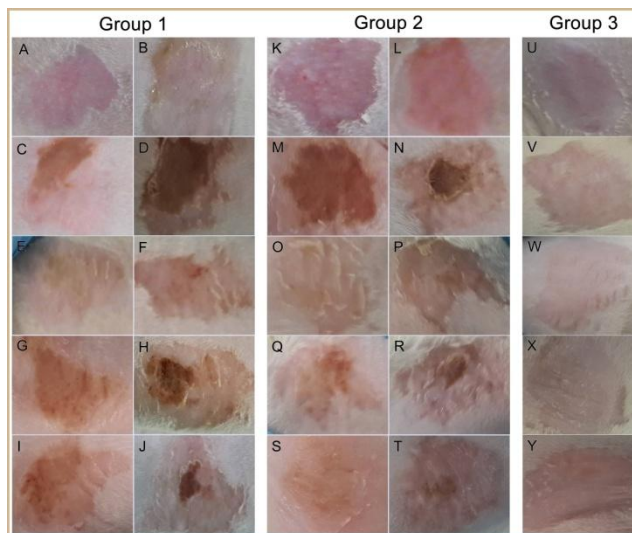


Fig. 3—Clinical findings Group 1, Group 2 and Group 3. Group 1 (A-J), (A) 0th h before bacterial inoculation in Group 1.4 (infected control group), (B-J) After the bacterial inoculation and treatment B: 24th hour in Group 1.4, C: 40th h in Group 1.4, D: 72nd h in Group 1.4, E: 40th h in Group 1.1 (ozonated olive oil treated group), F: 72nd h in Group 1.1, G: 40th h in Group 1.2 (olive Oil group), H: 72nd h in Group 1.2, I : 40th h in Group 1.3 (fucidic acid treated group), J: 72nd h in Group 1.3, Group 2 (K-T), K: 0th h before bacterial inoculation in Group 2.4 (infected control group), (L-T) After the bacterial inoculation and treatment L: 24th h in Group 2.4, M: 40th h in Group 2.4, N: 80th h in Group 2.4, O: 40th h in Group 2.1 (ozonated olive oil treated group), P: 80th h in Group 2.1, Q: 40th h in Group 2.2 (olive oil group), R: 80th h in Group 2.2, S : 40th h in Group 2.3 (fucidic acid treated group), T: 80th hour in Group 2.3 Group 3 (U-Y), U: 0th h in Group 3 (control group), V: 24th h in Group 3, X: 40th h in Group 3, W: 72nd h in Group 3, Y: 80th h in Group 3.

Discussion

OZO is widely used for the therapeutic efficacy of the antimicrobial activity against bacteria, viruses and fungi^{5,22,26}. When ozone is used topically on the skin, it has been shown to have an antibacterial effect by some researchers¹³⁻¹⁵. Lezcano *et al.*²⁶ have investigated ozonated sunflower oil (OSO) on to the susceptibility to bacteria, according to the method of microdilution. They found Minimum inhibitory concentration (MIC) 9.5 µg/mL for the strain *S. aureus* ATCC 25923. Sechi *et al.*⁵ also found similar results.

On the contrary to the earlier studies^{5,26}, here, the OZO on to the susceptibility was determined to be 0.25 µg/mL as MICs value for the strain of *S. aureus* ATCC 25923 according to the microdilution method (Table 1). Sechi *et al.*⁵, who have also investigated ozonated sunflower oil on to the susceptibility to bacteria according to the method of microdilution found MICs value as 9.5 µg/mL for the *S. pyogenes* strain which was a clinical isolate.

Table 4—Clinical healing in Group 1 and Group 3 which made according to clinical score

Groups	40 th hour $\bar{x} \pm ss$ <i>m(min-max)</i>	48 th hour $\bar{x} \pm ss$ <i>m(min-max)</i>	56 th hour $\bar{x} \pm ss$ <i>m(min-max)</i>	64 th hour $\bar{x} \pm ss$ <i>m(min-max)</i>	72 nd hour $\bar{x} \pm ss$ <i>m(min-max)</i>
G. 1. 1 (n=10)	1.00 ± 0.00 ^b 1.00 (1.00-1.00)	1.28 ± 0.48 ^c 1.00 (1.00-2.00)	1.33 ± 0.51 ^{bc} 1.00 (1.00-2.00)	1.80 ± 0.44 ^b 2.00 (1.00-2.00)	2.67 ± 0.00 ^b 2.00 (2.00-2.00)
G. 1. 2 (n=10)	0.00 ± 0.00 ^a 0.00 (0.00-0.00)	0.00 ± 0.00 ^a 0.00 (0.00-0.00)	0.00 ± 0.00 ^a 0.00 (0.00-0.00)	0.00 ± 0.00 ^a 0.00 (0.00-0.00)	0.00 ± 0.00 ^a 0.00 (0.00-0.00)
G. 1. 3 (n=10)	0.00 ± 0.00 ^a 0.00 (0.00-0.00)	1.00 ± 0.00 ^d 1.00 (1.00-1.00)	1.16 ± 0.40 ^c 1.00 (1.00-1.00)	1.80 ± 0.44 ^b 1.00 (1.00-1.00)	2.00 ± 0.00 ^b 1.00 (1.00-1.00)
G. 1. 4 (n=11)	0.00 ± 0.00 ^a 0.00 (0.00-0.00)	0.00 ± 0.00 ^a 0.00 (0.00-0.00)	0.00 ± 0.00 ^a 0.00 (0.00-0.00)	0.00 ± 0.00 ^a 0.00 (0.00-0.00)	0.00 ± 0.00 ^a 0.00 (0.00-0.00)
G. 3 (n=11)	1.00 ± 0.00 ^b 1.00 (1.00-1.00)	1.00 ± 0.00 ^b 1.00 (1.00-1.00)	1.00 ± 0.00 ^b 1.00 (1.00-1.00)	1.00 ± 0.00 ^b 1.00 (1.00-1.00)	1.00 ± 0.00 ^{ab} 1.00 (1.00-1.00)
<i>p</i>	<0.001	<0.001	<0.001	<0.001	0.001

[Different letters in the same *column* determine statistical significance ($P < 0.05$)]

Table 5—Clinical healing in Group 2 and Group 3 which made according to clinical score

Groups	40 th hour $\bar{x} \pm ss$ <i>m(min-max)</i>	48 th hour $\bar{x} \pm ss$ <i>m(min-max)</i>	56 th hour $\bar{x} \pm ss$ <i>m(min-max)</i>	64 th hour $\bar{x} \pm ss$ <i>m(min-max)</i>	72 nd hour $\bar{x} \pm ss$ <i>m(min-max)</i>
G. 2. 1 (n=10)	1.00 ± 0.00 ^b 1.00 (1.00-1.00)	1.28 ± 0.48 ^b 1.00 (1.00-2.00)	1.66 ± 0.51 ^b 2.00 (1.00-2.00)	2.00 ± 0.00 ^b 2.00 (2.00-2.00)	2.75 ± 0.50 ^p 3.00 (2.00-3.00)
G. 2. 2 (n=10)	0.00 ± 0.00 ^a 0.00 (0.00-0.00)	0.00 ± 0.00 ^{ac} 0.00 (0.00-0.00)	0.00 ± 0.00 ^a 0.00 (0.00-0.00)	0.00 ± 0.00 ^a 0.00 (0.00-0.00)	0.00 ± 0.00 ^a 0.00 (0.00-0.00)
G. 2. 3 (n=10)	0.00 ± 0.00 ^a 0.00 (0.00-0.00)	1.00 ± 0.00 ^c 1.00 (1.00-2.00)	1.33 ± 0.51 ^b 1.00 (1.00-2.00)	1.25 ± 0.50 ^{ab} 1.00 (1.00-2.00)	2.00 ± 0.00 ^{ab} 2.00 (2.00-2.00)
G. 2. 4 (n=11)	0.00 ± 0.00 ^a 0.00 (0.00-0.00)	0.00 ± 0.00 ^a 0.00 (0.00-0.00)	0.00 ± 0.00 ^a 0.00 (0.00-0.00)	0.00 ± 0.00 ^a 0.00 (0.00-0.00)	0.00 ± 0.00 ^a 0.00 (0.00-0.00)
G. 3 (n=11)	1.00 ± 0.00 ^b 1.00 (1.00-1.00)	1.00 ± 0.00 ^b 1.00 (1.00-1.00)	1.00 ± 0.00 ^{ab} 1.00 (1.00-1.00)	1.00 ± 0.00 ^{ab} 1.00 (1.00-1.00)	1.00 ± 0.00 ^{ab} 1.00 (1.00-1.00)
<i>P</i>	<0.001	<0.001	<0.001	<0.001	0.001

[Different letters in the same *column* determine statistical significance ($P < 0.05$)]

Furthermore, in the present study, according to microdilution method, OZO on to the susceptibility was determined 0.25 µg/mL MICs value for the *S. pyogenes* strain also which was a clinical isolates (Table 1). The difference obtained in the present study may be due to ozonation time, peroxide, acid, iodine, p-anisidine and viscosity values²².

Ozone breaks down protein in spite of the amino acid tryptophan residues and molecular weight difference. The implementation of this system, to treat skin infections can be more extensive and comprehensive caused by *S. aureus* infection^{5,27}. Lezcano *et al.*²⁷ reported that OSO does not harm human epithelium and has significant antibacterial property. Diaz *et al.*²⁸ have also reported that OSO and OZO, has an effective antibacterial activity against bacteria in human being.

In the present study, histopathological examination has shown the presence of bacteria in Group 1.1 (18.2%) and in Group 1.4, it was 100%. The OZO caused significant reduction ($P < 0.001$) in the presence of bacteria compared to Group 1.4 (Table 2). In Group 2.1, the presence of bacteria was 45.5% and

in Group 2.4 it was 100% wherein OZO caused significant reduction ($P < 0.001$) in the presence of bacteria compared to Group 2.4 (Table 3). Our findings for both *S. aureus* and *S. pyogenes* were in agreement with literature findings mentioned above.

FA has been used to treat impetigo, infected wounds, abscess, infections of eye, skin and mucosa caused by *Streptococcus*, *Staphylococcus* and other gram positive bacteria^{4,29}. Rodrigues *et al.*³⁰ made 6 mm wound on the skin of rat and infected the lesion with *S. aureus* ATCC 6538 strain. They applied OSO (35 mg) on to the wound. They also used neomycin (clostebol) for treatment and for comparison. They found OSO as effective as neomycin in terms of antimicrobial and anti-inflammatory effects. Our findings were in parallel with these findings, in Group 1.1 with concern to presence of bacteria; no statistical difference was observed compared to Group 1.3 (Table 2). Furthermore, Group 2.1 was not different statistically compared to Group 2.3 (Table 3).

Particularly on the wound, ozone causes an increase in the activity of growth factors.

Accordingly, angiogenesis, fibroblast activity and collagen synthesis increased³¹⁻³³. Platelet derived growth factor (PDGF), transforming growth factor (TGF- β) and vascular endothelial growth factor (VEGF) increase in fibroblast proliferation and collagen synthesis revealed acceleration of wound healing³⁴⁻³⁷. Kim *et al.*³⁸ have compared the local effects of OZO and OL that was used in wound healing in guinea pigs. In their study, they found that OZO to be more effective compared to the control group and OL group. They also reported that OZO caused increase in fibroblast proliferation and collagen synthesis revealing accelerated wound healing, which could be due to PDGF, TGF- β and VEGF at the wound site. Bactericidal effects of ozone, as well as its derivative, are the first phase of wound healing. Also, OZO reduces the presence of phagocytic cells, consequently reduces oxidative burst and increase the oxygen tension and supports dermal wound healing³⁴.

Apart from the antibacterial activity of ozone on the skin and wound repair, it also increases wound oxygenation properties³²⁻³⁴. Curro *et al.*³⁹ have also determined the effects of an innovative formulation of OZO with vitamin E acetate on male children with Balanitis xerotica obliterans (BXO). OZO with vitamin E showed effective results in children affected by BXO by reducing the inflammatory process and stimulating mechanisms for tissue regeneration of the foreskin. This indicates that in the present study; when groups compared with concern to recovery; between Group 1.1 and Group 1.4 at 40, 48, 56, 64, 72 and 80 h after infection, recovery were also better ($P < 0.001$) in Group 1.1 compared to Group 1.4 likewise, between Group 1.1 and Group 1.2 at 40, 48, 56, 64 and 72 h after infection, recovery were also better ($P < 0.001$) in Group 1.1 compared to Group 1.2 (Table 4).

When groups were compared with concern to recovery; between Group 2.1 and Group 2.4 at 40, 48, 56, 64, 72 and 80 h after infection, the recovery were also better ($P < 0.001$) in Group 2.1 compared to Group 2.4. Likewise, between Group 2.1 and Group 1.4 at 40, 48, 56, 64 and 72 h after infection, recovery were also better ($P < 0.001$) in Group 2.1 compared to Group 2.2 (Table 5).

Furthermore, with concern to dermal lesions, in papillary dermis and subcutis, inflammatory cells was higher ($P < 0.001$) in Group 1.4 compared to Group 1.1. But, statistical importance were not observed in

reticular dermis both in Group 1.4 and Group 1.1 and also more number of inflammatory cells were determined (Table 2). Additionally, with concern to dermal lesions, in reticular dermis, inflammatory cells was higher ($P < 0.001$) in Group 2.4 compared to Group 2.1. But, statistical importance was not observed in papillary dermis and subcutis in both Group 2.4 and Group 2.1 and also more number of inflammatory cells were determined (Table 3). This is considered to suggest that OZO acting by both antibacterial and anti-inflammatory effects. These support Valacchi *et al.*³³ findings.

Estrela *et al.*⁴⁰ reported that ozone is effective on Staphylococcus. Furthermore, Schulz⁴¹ had proven the effect of ozone on burn and wound who was investigated on animals. In addition, Schulz⁴¹ found that ozonated oil had 40% better healing effect applied for 11 days on wound compared to other pomades. Song *et al.*⁴² were determined the microbial effects of topical ozone treatment on *S. aureus* and MRSA. After their study the inhibition zone diameters of OZO for *S. aureus* and MRSA were 17 and 13 mm, respectively, which were significantly larger than the control group. And also all cases of skin *S. aureus* and MRSA infection were completely healed after ozone treatment.

In the present study, according to microdilution method and disc diffusion test, although FA were more effective against *S. pyogenes* compared to OZO (Table 1), in Group 1.1; healing started at 40th h (Fig. 3E) and complete recovery observed at 72 h after infection (Fig. 1F & 3), but in Group 1.3, healing started at 48th h and complete recovery seen at 80 h after infection. In Group 1.3 at 72 h after infection, absence of inflammatory reactions and presence of hyperkeratosis on the epithelial tissue were observed (Fig. 1E).

Although FA were more effective against *S. aureus* compared to OZO in disc diffusion test (Table 1), in Group 2.1, healing started at 40th h (Fig. 3O) and complete recovery observed at 80 h after infection (Fig. 2F and Fig. 3P), but in Group 2.3, healing started at 48th h and complete recovery seen at 80 h (Fig. 3T) after infection, even though, absence of inflammatory reactions and presence of hyperkeratosis were observed on the epithelial tissue (Fig. 2E). As a result, in ozone applied groups, healing started earlier, and hence complete recovery observed earlier. The reasons could be due to; in addition to antibacterial and anti-inflammatory effect

of ozone, its increasing effect on collagen synthesis, fibroblast proliferation, epithelisation and vascularisation that accelerate healing process.

Conclusion

As a result, in the present study, experimental skin infections with *Streptococcus pyogenes* and *Staphylococcus aureus* were made and the effects of OZO in the treatment of the infection were evaluated and results were compared with other treatment methods. After occurrence of the infection, 0.1 g OZO had antimicrobial and anti-inflammatory effect and observed to have healing activity at 72 and 80 h after infection. Furthermore, the effects of OZO were comparable with the effects of FA which is well known and its activity has been proven in the skin infections with *Staphylococcus* and *Streptococcus*. Additionally, as far as known microorganisms has no resistance development against ozone and has no important side effects.

Acknowledgement

This study was taken from a Ph. D thesis which was supported by The Research Projects Coordination Unit of University of Afyon Kocatepe, Turkey as 13.Sag.Bil.10 project number.

References

- Quinn PJ, Carter ME, Markey BK & Carter GR, *Clinical Veterinary Microbiology*. 1st edn. (Wolfe Publishing, London), 1994, 109.
- Demir B, Denk A, Karlıdag GE & Ucak H, Antibiotic Susceptibility of Microorganisms Isolated from the Bacterial Skin Infections and Evaluation of Empirical Antibiotic Therapy. *F Ü Sag Bil Tip Derg*, 28 (2014) 5.
- Lio PA & Kaye ET, Topical Antibacterial Agents. *Infect Dis Clin N Am*, 18 (2004) 717.
- Gelmetti C, Local antibiotics in dermatology. *Dermatol Ther*, 21 (2008) 187.
- Sechi LA, Lezcano I, Nunez N, Espim M, Dupre I, Pinna A, Molicotti P, Fadda G & Zanetti S, Antibacterial activity of ozonized sunflower oil. *J Appl Microbiol*, 90 (2001) 279.
- Shinriki N, Ishizaki K, Ikehata A, Yoshizaki T, Nomura A, Miura K & Mizuno Y, Degradation of nNucleic Acid with Ozone. *Biochim Biophys Acta*, 655 (1981) 323.
- Anas K, Jayasree, PR, Vijayakumar T & Kumar PM, In vitro antibacterial activity of Psidium guajava Linn. leaf extract on clinical isolates of multidrug resistant *Staphylococcus aureus*. *Indian J Exp Biol*, 46 (2008) 41.
- Singh V, Praveen V, Banga J & Tripathi CKM, Antimicrobial activities of microbial strains isolated from soil of stressed ecological niches of Eastern Uttar Pradesh, *Indian J Exp Biol*, 47 (2009) 298.
- Deshpande SD & Kulkarni KS, In vitro effect of some India honeys on *Staphylococcus aureus* from wounds. *Indian J Exp Biol*, 48 (2010) 931.
- Abraham G, Yadav RK & Kaushik GK, Antimicrobial activity and identification of potential antimicrobial compounds from aquatic pteridophyte, *Azolla microphylla* Kaulf. *Indian J Exp Biol*, 53 (2015) 232.
- Tian C, Zhao C, Zhang D, Yang C, Guo Y, & Liu M, Extraction procedure and antibacterial activity in vitro of total phenol extract from *Abutilon theophrasti* Medic. Leaves. *Indian J Biochem Biophys*, 54 (2017) 121.
- Bocci V, *Ozone. a new medical drug*. 2nd edn. (Dordrecht, The Netherlands: Springer), 2011, 1.
- Pryor WA & Uppu RM, A kinetic model for the competitive reaction of Ozone with amino acid residues in proteins in reverse micelles. *J Biol Chem*, 268 (1993) 3120.
- Beck EG, Wasser G & Viebahn-Hansler R, The current status of ozone therapy empirical developments and basic research review article. *Forsch Komplementarmed*, 5 (1998) 61.
- Maslennikov OV, Kontorshchikova CN and Gribkova IA, *Ozone therapy in practice. health manual*. (Nizhny Novgorod Russia), 2008, 6.
- Elvis AM & Ekta JS, Ozone therapy: a clinical review. *J Nat Sci Biol Med*, 2 (2011) 66.
- Kugelberg E, Norström T, Petersen TK, Duvold T, Andersson DI & Hughes D, Establishment of a Superficial Skin Infection Model in Mice by Using *Staphylococcus aureus* and *Streptococcus pyogenes*. *Antimicrob Agents Chemother*, 49 (2005) 3435.
- AOCS, Acid Value. AOCS Official Test Method Cd 3a-63 for. In: *Official Methods and Recommended Practices of the American Oil Chemists' Society*, 5th edn. edited by Firestone D, (American Oil Chemists' Society, Champaign, IL, USA), 1998a
- AOCS, AOCS official Method Cd 1-25: Iodine Value of Fats and Oils. Wijs Method. In: *Official Methods and Recommended Practices of the American Oil Chemists' Society*, 5th edn. edited by Firestone D, (American Oil Chemists' Society, Champaign, IL, USA), 1998b.
- AOCS, Peroxide value. AOCS official method Cd 8-53.. In: *Official Methods and Recommended Practices of AOCS*, 5th edn. edited by Firestone D, (American Oil Chemists' Society, Champaign, IL, USA), 1998c.
- AOCS, P-anisidine value. AOCS Method Cd 18-90(11): official method. In: *Official Methods and Recommended Practices of the American Oil Chemists' Society*, 6th edn. (Ed. Firestone D; American Oil Chemists' Society, Champaign, IL, USA), 2011.
- Geweely, NSI, Antifungal activity of Ozonated olive oil. *Int J Agr Biol*, 8 (2006) 670.
- Travagli V, Zanardi I, Valacchi G & Bocci V, Ozone and ozonated oils in skin diseases: a review. *Mediators of inflamm*, (2010) 1.
- CLSI, Performance standards for antimicrobial disc susceptibility tests; approved standard M02-A10, 10th edn. (Clinical and Laboratory Standards Institute, Wayne PA), 2009.
- CLSI, Methods for dilution antimicrobial susceptibility tests for bacteria that grow aerobically; approved standard M07-A8, 8th edn. (Clinical and Laboratory Standards Institute Wayne PA), 2009.
- Lezcano I, Nunez N, Gutierrez M, Molerio J, Regeiferos MG & Diaz W, Actividad in vitro del aceite de girasol

- ozonizado (Oleozon) frente a diferentes especies bacterianas. *Rev CENIC Cienc Bio*, 29 (1998) 46.
- 27 Lezcano I, Nuiez N, Espino M & Gomez M, Antibacterial Activity Of Ozonized Sunflower Oil, Against *Staphylococcus aureus* and *Staphylococcus epidermis*. *Ozone Sci Eng*, 22 (2000) 207.
- 28 Diaz MF, Hernandez R, Martinez G, Vidal G, Gomez M, Fernandez H & Garces R, Comparative study of ozonized olive oil and ozonized sunflower oil. *J Braz Chem Soc*, 17 (2006) 403.
- 29 Melli M & Kayaalp SO, Antibiyotikler ve diğer kemoterapatikler. In *Tıbbi Farmakoloji Cilt 1* edited by Kayaalp SO (Ertem basım Ltd. Ankara), 2012, 157.
- 30 Rodrigues, KL, Cardoso CC, Caputo LR, Carvalho JCT, Fiorini JE & Schneedorf JM, Cicatrizing and antimicrobial properties of an ozonised oil from sunflower seeds. *Inflammopharmacology*. 12 (2004) 261.
- 31 Gajendrareddy PK, Sen CK, Horan MP & Marucha PT, Hyperbaric oxygen therapy ameliorates stress-impaired dermal wound healing. *Brain Behav Immun*, 19 (2005) 217.
- 32 Lim Y, Phung AD, Corbacho AM, Aung HH, Maioli E, Reznick AZ, Cross CE, Davis PA & Valacchi G, Modulation of Cutaneous Wound Healing By Ozone: Differences Between Young and Aged Mice. *Toxicol Lett*, 160 (2006) 127.
- 33 Valacchi G, Lim Y, Belmonte G, Miracco C, Zanardi I, Bocci V & Travagli V, Ozonated sesame oil enhances cutaneous wound healing in SKH1 mice. *Wound Repair Regen*, 19 (2011) 107.
- 34 Goel A, Kumar S, Kumar Singh D & Kumar Bhatia A, Wound healing potential of *Ocimum sanctum* Linn. with induction of tumor necrosis factor- α . *Indian J Exp Biol*, 48 (2010) 402.
- 35 Gopalakrishnan A, Ram M, Kumawat S, Tandan SK & Kumar D, Quercetin accelerated cutaneous wound healing in rats by increasing levels of VEGF and TGF- β 1. *Indian J Exp Biol*, 54 (2016) 187.
- 36 Karimzadeh S & Farahpour MR, In the treatment of skin infections caused by bacteria, both systemic and local treatment can be applied. But topical treatment more often used *Indian J Exp Biol*, 55 (2017) 98
- 37 Dabhi B, Mistry KN, Patel H & Lal S, Vascular endothelial growth factor insertion/deletion gene polymorphism in West Indian patients of type 2 diabetes and diabetic nephropathy. *Indian J Biochem Biophys*, 52 (2015) 209.
- 38 Kim HS, Noh SU, Han YW, Kim KM, Kang H, Kim HO & Park YM, Therapeutic effects of topical application of ozone on acute cutaneous wound healing. *J Korean Med Sci*, 24 (2009) 368.
- 39 Curro M, Russo T, Ferlazzo N, Caccamo D, Antonuccio P, Arena S, Parisi S, Perrone P, Ientile R, Romeo C & Impellizzeri P, Anti-Inflammatory and Tissue Regenerative Effects of Topical Treatment with Ozonated Olive Oil/Vitamin E Acetate in Balanitis Xerotica Obliterans. *Molecules*, 23 (2018) 645.
- 40 Estrela C, Estrela CR, Decurcio DDA, Silva JA & Bammann LL, Antimicrobial potential of ozone in an ultrasonic cleaning system against *Staphylococcus aureus*. *Braz Dent J*, 17 (2006) 134.
- 41 Schulz SA, New animal model for the integral measurement of healing processes in small laboratory animals with ozonized olive oil as example. *Ger Vet Med Weekly*, 88 (1981) 60.