

Evaluation of protective effects of ethanolic extract of *Costus speciosus* (Koenig) Sm. rhizomes on carbon tetrachloride induced hepatotoxicity in rats

Nitin Verma* and R L Khosa

Department of Pharmaceutical Technology, Bharat Institute of Technology, Partapur Bypass, NH#58, Meerut-250 005, Uttar Pradesh, India

*Correspondent author, E-mail: nitinmiet14@rediffmail.com, nitinmiet1482@gmail.com

Phone: +91 121 24001877, (0)9897222975 (Mob)

Received 3 March 2008; Accepted 22 September 2008

Abstract

The hepatoprotective activity of the ethanolic extract of the rhizomes of *Costus speciosus* (Koenig) Sm. was studied on carbon tetrachloride treated rats. The extract registered a significant fall in the levels of serum glutamyl oxalacetic acid transaminase (SGOT), serum glutamyl pyruvate transaminase (SGPT), alkaline phosphatase (ALKP), serum bilirubin (SBLN) and liver inflammation supported by histopathological studies on liver, thus exhibited a significant hepatoprotective activity.

Keywords: *Costus speciosus*, Carbon tetrachloride, Ethanolic extract, Hepatoprotective activity, Lipid peroxidation.

IPC code; Int. cl.⁸ — A61K 36/00, A61K 36/906, A61K 125/00, A61P 1/16



Plant of *Costus speciosus*



Rhizome of *Costus speciosus*

Introduction

The liver is the prime organ concerned with various states of metabolic and physiologic homeostasis of the organism¹. In modern medicine there is no specific cure for such fearful diseases as infectious hepatitis and liver cirrhosis. Treatment of many liver diseases is symptomatic and often disappointing since much is still obscure about their etiology. There is, however, a plethora of drugs in the indigenous system of medicine said to be useful in these diseases².

Costus speciosus (Koenig) Sm. (Family—Zingiberaceae) commonly known as *Keukand* or *Kustha* in Hindi is an erect plant up to 2.7 m high. It is used in Ayurvedic system of medicine as an anti-inflammatory, anthelmintic, astringent, bitter, depurative, purgative and as stimulant. The plant is also used as anti-diabetic³. It has been reported that

its rhizomes contains diosgenin, prosapogenin B of dioscin, diosgenone, cycloartanol, 25-en cycloartenol octacosanoic acid, spirostanol glycoside (steroid saponins), and furostanol glycoside 26-O- β -glucosidase. Quinones like 6-methyl dihydrophytylplastoquinone and dihydrophytylplastoquinone are also reported in plant⁴.

In Meghalaya, the decoction of rhizomes and those of *Cyperus rotundus* Linn. and the bark of *Azadirachta indica* A. Juss. is given in jaundice⁵. Considering these facts an experimental investigation was carried out to explore the use of this drug as a hepatoprotective agent. This protection was judged in carbon tetrachloride (CCl₄) induced liver toxicity in albino rats because the changes associated with CCl₄ - induced liver damage are similar to that of acute viral hepatitis⁶ and it is one of

the internationally accepted models for hepatotoxicity in the screening of herbals for their hepatoprotective effects in rats.

Materials and Methods

Plant material

The rhizomes of *C. speciosus* were procured from the Plant Physiology Division, Jawaharlal Nehru Krishi Vishwa Vidyalaya, Krishi Nagar, Jabalpur and

authenticated by Dr. Anjula Pandey of Taxonomic Division, National Herbarium of Cultivated Plants, National Bureau of Plant Genetic and Resources, Pusa Campus, New Delhi. A voucher specimen (NHCP/NBPGR/2007/98/2225 dated 22/08/2007) was retained in our laboratory for further reference.

Plant extract

The plant material was dried under shade, reduced to moderately coarse powder and was extracted successively with petroleum ether (60-80°C) and ethanol using Soxhlet apparatus. The ethanolic extract was dried under vacuum (yield 10.78%) and its qualitative analysis showed the presence of phenolic compounds, saponins, reducing sugars and glycosides. The ethanolic extract of *C. speciosus* (CSEE) was used for the present studies.

Animals

Wistar albino rats of both sexes (130-170g) were used for the present studies. They were housed in clean polypropylene cages (38×23×10 cm) with not more than six animals per cage and maintained under standard laboratory condition (temperature 25±2°C) with dark and light cycle (12/12 h). They were provided standard pellet diet (Hindustan Lever, Kolkata, India) and water *ad libitum*. The Institutional Animal Ethics Committee (IAEC) approved the use of animals for the studies (Ethical clearance number: 711/02/a/CPCSEA).

Assessment of hepatoprotective activity^{7,8}

The rats were divided into four groups of six rats each. The animals of

group A and B served as control and carbon tetrachloride control received vehicle (0.1% Tween 80 10ml/kg b.w.). Group C served as standard and received Silymarin (100 mg/kg b.w. in 0.1% Tween 80), and group D was given alcoholic extract of *C. speciosus* rhizome (500 mg/kg b.w. in 0.1% Tween 80). All administration of doses was made by gastric intubations once daily for seven days.

On the 8th day one hour after the administration of last dose, the animals of group B, C and D were given an intraperitoneal injection of carbon tetrachloride with an equal quantity of liquid paraffin (0.5 ml/kg b.w.). All the animals were then fasted for 24 h after which they were anaesthetized and the blood was collected by cardiac puncture. The liver was quickly dissected, washed with ice-cold saline and stored in freezer. The blood samples were allowed to coagulate at room temperature for one hour. Serum was separated by centrifugation at 12,000 rpm at 4°C for 5 minutes.

Biochemical studies

Serum was analyzed for various biochemical parameters, i.e. serum glutamyl oxalacetic acid transaminase (SGOT, AST), serum glutamyl pyruvate transaminase (SGPT, ALT)⁹, and alkaline phosphatase (ALKP)¹⁰ and for serum bilirubin¹¹.

Histopathological studies

The hepatoprotective activity was confirmed through histopathological studies on liver of rats. Slices of liver were cut and washed in Ringer's solution which then soaked with filter paper for 1.5 min

then liver slices were fixed in Carnoy's fluid I (Ethanol: Chloroform: Glacial acetic acid — 6:3:1) and processed for paraffin embedding following the standard microtechniques. Section of liver, stained with aqueous haematoxylin and alcoholic eosin were observed microscopically for histopathological changes¹².

Statistical analysis

The data represent mean ± S.E.M. Results were analyzed statistically by one-way ANOVA followed by Student's 't' test. The minimum level of significance was set at $P < 0.001$ compared to control.

Results and Discussion

Results indicated that the ethanolic extract of the rhizomes of *C. speciosus* provides significant protection against the toxic effect of CCl₄ on liver. The effects of ethanolic extracts at a dose level (500 mg/kg b.w. in 0.1% Tween 80) showed recovery against the toxic effects of CCl₄ on serum marker enzymes and total bilirubin compare to Silymarin treated group as shown in the Table-1. Hepatic injury induced by CCl₄ caused significant rise in marker enzymes SGPT, SGOT, ALP and serum bilirubin and caused a subsequent recovery towards normalization almost like that of Silymarin treatment. Histological profile of the ethanolic extract treated animals showed the recovery against the CCl₄ induced necrosis in their normal compact arrangement of hepatic cells. Whereas, the section of the animals treated with Silymarin showed moderate accumulation of fatty lobules around the vein but the extent of liver damage was lesser in magnitude as compared to the CCl₄ treated animals (Fig.1 a-d). The results of this

Table 1 : Effect of ethanolic extract of *Costus speciosus* rhizomes on CCl₄ induced hepatotoxicity in rats

Parameters, Groups	Biochemical Parameters					
	SGPT(IU/l)	SGOT(IU/l)	SALP(IU/l)	Bilirubin(mg/dl)		
				Total	Direct	Liver weight (g)
Group A: Control	53.25±3.83	382.50±21.32	196.68±1.09	0.93±0.03	0.17±0.08	3.21±0.22
Group B: Toxicant (Induction control)	268.32±23.04***	702.45±6.6***	489.23±5.7***	3.14±0.24***	1.29±0.25***	3.38±0.24**
Group C: Standard (Positive control)	78.67±7.33	408.29±4.68	213.55±4.27	1.64±0.82	0.19±0.03	3.22±0.01
Group D: Ethanolic extract (500mg/kg b.w.)	104±9.75*	438.00±7.0**	249.59±6.07*	1.82±0.38**	0.24±0.88*	3.32±0.10**

Note: n= six animals in each group; Values are expressed as mean ± SEM; * $p < 0.05$ compared to control; ** $p < 0.02$ compared to control; *** $p < 0.001$ compared to control

investigation indicated that the ethanolic extract of *C. speciosus* possess hepatoprotective activity against CCl₄ induced liver damage in rats.

The ability of a hepatoprotective drug to reduce the injurious effects or to preserve the normal hepatic physiological mechanisms that have been disturbed by a hepatotoxin is the index of its protective effects¹³. The hepatotoxicity induced by CCl₄ is due to its metabolite CCl₃^{*}, a free radical that alkylates cellular proteins and other macromolecules with a simultaneous attack on polyunsaturated fatty acids, in the presence of oxygen, to produce lipid peroxides, leading to liver damage¹⁴. Hepatocellular necrosis leads to elevation of the serum marker enzymes, which are released from the liver into blood¹⁵. The increased levels of SGOT, SGPT, ALP and serum bilirubin are conventional indicators of liver injury¹⁶.

The present study revealed significant increase in the activities of SGOT, SGPT, ALP and serum bilirubin levels on exposure to CCl₄ indicating considerable hepatocellular injury. Administration of ethanolic extract of the rhizomes of *C. speciosus* at a dose level (500 mg/kg b.w. in 0.1% Tween 80) attenuated the increased levels of the serum enzymes, produced by CCl₄ and caused a subsequent recovery towards normalization almost like that of Silymarin treatment. The hepatoprotective effect of the drug was further concluded by the histopathological examination. The result showed that the drug at a dose level (500mg/kg b.w.) offers a significant hepatoprotection. This may be due to rich content of the steroidal saponins and glycosides in the rhizomes of *C. speciosus*; as hepatoprotective action of certain steroidal saponins and

glycosides has been well documented in the literature.

Conclusion

In conclusion, the remarkable results of this experiment are the decrease in the content of hepatic markers (SGOT, SGPT, ALP and bilirubin). The ethanolic extract of *C. speciosus* rhizomes showed better results in comparison with Silymarin. In addition its ethanolic extract also prevented the increase in liver weight, liver inflammation and necrosis induced by CCl₄. These data along with the histopathological studies clearly shows the hepatoprotective activity and justifies the use of this plant in folk medicine for jaundice. Further studies are in progress to identify active principle(s) responsible for is hepatoprotection and to find out synergy among different compounds present in *C. speciosus*.

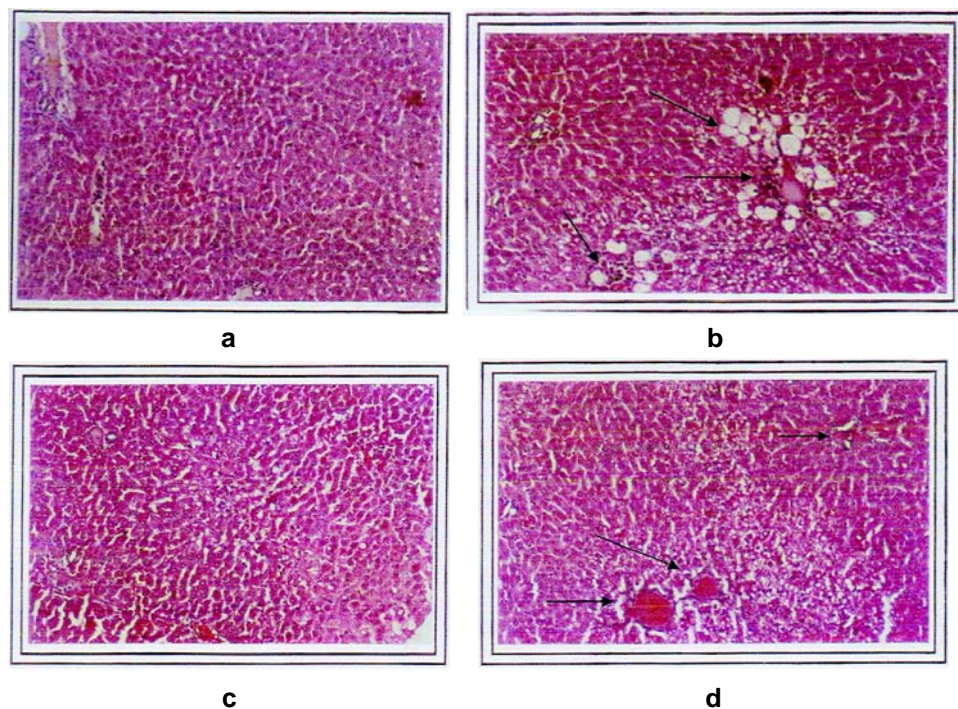


Fig. 1 (a-d): Histopathology of liver tissues at X 400 magnification: (a) Group I (control) - section shows central vein surrounded by hepatic cord of cells (normal architecture), (b) Group II (CCl_4 treated) - section shows patches of liver cell necroses, inflammatory collections and accumulation of fatty lobules around central vein, (c) Group III (Standard silymarin treated) - almost near normal, (d) Group IV (treated with ethanolic extract of *C. speciosus* rhizomes) - minimal inflammatory cellular infiltration, almost near normal liver architecture, regeneration of hepatocytes around central vein.

Acknowledgement

The authors are thankful to the Taxonomic Division, National Herbarium of Cultivated Plants, National Bureau of Plant Genetic and Resources, New Delhi for plant's identification and its authentication.

References

- Brodie BB, Pathways of drug metabolism, *J Pharm Pharmacol*, 1956, **8**(2), 1-17.
- Karandikar GV, Chitle GK and Balwani JH, Protection by indigenous drugs against hepatotoxic effects of CCl_4 - a long term study, *Acta Pharmacol*, 1963, **20**(11), 274-280.
- Vijayalaxmi MA and Sarada NC, Screening of *Costus speciosus* extracts for antioxidant activity, *Fitoterapia*, 2008, **79**(3), 197-198.
- Inoue K and Ebizuka Y, Purification and characterization of Furostanol glycoside 26-O- β -glucosidase from *Costus speciosus* rhizomes, *FEBS Lett*, 1996, **378**(2), 157-160.
- The Wealth of India, First Supplement series (Raw Materials), National Institute of Science Communication, CSIR, New Delhi, Vol-2, 2001, pp. 213-214.
- Sanmugapriya E and Venkataraman S, Studies on hepatoprotective and antioxidant actions of *Strychnos potatorum* Linn. Seeds on CCl_4 -induced acute hepatic injury in experimental rats, *J Ethnopharmacol*, 2006, **105**, 154-160.
- Khosa RL, Padma P and Chansouria PN, Hepatoprotective activity of *Annona muricata* Linn. and *Polyalthia cerasoides* Bedd, *Ancient Sci Life*, 1998, **19**(1&2), 7-10.
- Verma N, Khosa RL and Pathak AK, Hepatoprotective activity of fruits of *Ficus bengalensis* Linn., *Indian J Nat Prod*, 2007, **23**(2), 18.
- Reitman S and Frankel S, A colorimetric method for the determination of serum glutamic oxaloacetic acid, glutamic pyruvic transaminase, *Am J Clin Pathol*, 1957, **28**(7), 56-58.
- Bessey OA, Lowry OH and Bros MJ, A method for the rapid determination of alkaline phosphatase with five cubic millimeter of serum, *J Biol Chem*, 1946, **164**(2), 321-329.
- Malloy HT and Evelyn KA, The determination of bilirubin with the photoelectric colorimeter, *J Biol Chem*, 1937, **119**(7), 481-488.
- Galigher AE and Kozloff EN, Essential of Practical Microtechnique, Lea and Febiger, Philadelphia, 2nd Edn, 1971, p.77.
- Yadav NP and Dixit VK, Hepatoprotective activity of leaves of *Kalanchoe pinnata* Pers., *J Ethnopharmacol*, 2003, **86**, 197-202.
- Bishayee A, Sarkar A and Chatterjee M, The hepatoprotective activity of Carrot (*Daucus carota* L.) against carbon tetrachloride intoxication in mouse liver, *J Ethnopharmacol*, 1995, **47**, 69-74.
- Ashok Shenoy K, Somaayaji SN and Bairy KL, Evaluation of hepatoprotective activity of *Ginkgo biloba* in rats, *Indian J Pharmacol*, 2002, **46**(2), 167-174.
- Achliya GS, Wadodkar SG and Dorle AK, Evaluation of hepatoprotective effect of Amalkadi Ghrita against carbon tetrachloride induced hepatic damage in rats, *J Ethnopharmacol*, 2004, **90**, 229-232.