

Alleviation of lindane induced toxicity in testis of Swiss mice (*Mus musculus*) by combined treatment with vitamin C, vitamin E and α -lipoic acid

Girima Nagda* & Devendra Kumar Bhatt

Cancer Biology and Toxicology Research Laboratory, Department of Zoology, University College of Science,
M L Sukhadia University, Udaipur 313 001, India

Received 3 May 2010; revised 7 December 2010

Mitigation of lindane induced toxicity in testis of Swiss mice by combined treatment with vitamin C, vitamin E and α -lipoic acid has been evaluated. Male healthy mice (40), 8-10 weeks old were randomly selected and divided into 4 groups, control (C); lindane (L); antioxidant (A) and antioxidant plus lindane (A+L). Group C animals were administered only the vehicle (olive oil); in group L lindane was administered orally at a dose of 40 mg/kg body wt.; in group A combination of antioxidants at a dose of 125 mg/kg body wt. (vitamin C: 50 mg/kg body wt., vitamin E: 50 mg/kg body wt. and α -lipoic acid: 25 mg/kg body wt.) was administered orally; in group A+L both antioxidants (125 mg/kg body wt.) and lindane (40 mg/kg body wt.) were administered at their respective doses. In group A+L antioxidants were administered 1 h prior to lindane administration. All treatments were continuously given for 60 days. Histopathological changes due to lindane intoxication indicated shrunken and distorted seminiferous tubules, sparse Leydig cells and blood vessels and atrophy in the tissue. The testis weight also decreased significantly. Lindane treated group showed increased lipid peroxidation, whereas glutathione, glutathione peroxidase, superoxide dismutase, catalase and protein were significantly decreased compared to control. Lindane induced damage was minimized by administration of antioxidants. Results suggest that combined pretreatment with antioxidants can alleviate the damage caused to testis by lindane.

Keywords: Lindane toxicity, α -Lipoic acid, Testis, Vitamin C, Vitamin E

Gamete production, their transport, reproductive cycle, sexual behavior and fertility may be severely affected by xenobiotics. Large number of chemicals, pollutants, drugs and hormonal imbalances adversely affect the reproduction¹. Involvement of reactive oxygen species (ROS) has been suggested as one of the mechanisms through which most of the xenobiotics exert their deleterious effects on testis^{2,3}. Toxicity of such agents in testis may lead to testicular dysfunction, arrest of spermatogenesis and production of abnormal sperms⁴. Normal gamete formation in testis is a key factor in fertility and development.

Lindane, the γ -isomer (>99% pure) of hexachlorocyclohexane (γ -HCH) is an organochlorine pesticide extensively used to control malaria vectors and eradicate pests on agriculture crops⁵. Due to indiscriminate use and persistent nature, lindane residues are alarmingly high at different trophic levels in environment⁶. Consequently, lindane enters the food chain resulting in bioaccumulation, in the following order, in various tissues: fat > brain > kidney > muscle

> lung > heart > spleen > liver > blood^{7,8} and breast milk of humans⁹.

Testis is also susceptible to lindane as it crosses blood-testis barrier and depresses spermatogenesis¹⁰. Topical application of a commercial preparation of lindane in rats showed rapid absorption and accumulation in testis¹¹. Further, exposure to lindane has been reported to disturb male mammalian reproductive functioning^{4,12-14}.

Oxidative stress seems to play a critical role in the etiology of defective sperm formation, sperm count profile and male infertility^{15,16}. Presence of high level of ROS is linked with lipid peroxidation of the spermatozoal outer membrane, which leads to loss of motility¹⁷, decreased sperm-oocyte fusion capacity¹⁸, and increased chromatin damage¹⁹. Furthermore, once the integrity of spermatozoa becomes affected, they are unable to undergo repair because of deficiency in enzyme systems required, thereby rendering male germ cells particularly vulnerable to oxidative stress²⁰.

Lindane intoxication has been reported to generate free radicals in testis²¹⁻²³. Impact made by free radicals on lipids is named as lipid peroxidation

*Correspondent author
Telephone: +91 094603 15237
E-mail: girima.nagda@gmail.com

(LPO). LPO is a complicated radical chain reaction leading to the formation of various products including lipid hydroperoxides, conjugated dienes and malondialdehyde²⁴. LPO damages the sperm cell membrane and is considered to be the key mechanism of ROS-induced sperm damage leading to loss of motility, abnormal morphology and reduced capacity for sperm oocyte penetration and infertility²⁵.

Human body has a strong defense system to combat and counteract the damage caused by free radicals²⁶. In general, antioxidant systems either prevent these reactive species from being formed, or remove them before they can damage vital components of the cell²⁷. However, sometimes the homeostasis gets disturbed due to continuous exposure to toxicant or failure of endogenous antioxidant system. Thus, the balance between ROS production and antioxidant defense is lost causing oxidative stress which further deregulates cellular functions leading to various pathological conditions²⁸. The efforts of the endogenous antioxidant enzymes to remove the continuously generated free radicals initially increase due to an induction but later enzyme depletion results, resulting in oxidative cell damage²⁹. In order to overcome such adverse effects the most compatible source would be to supplement with exogenous antioxidants.

Potency of various antioxidants on different organ systems has been investigated against lindane toxicity³⁰⁻³³. Recently, combination of vitamin C, vitamin E, resveratrol and α -lipoic acid has been reported to be very efficient in reducing toxicity induced by lindane in different brain regions of mice^{33,34}.

However, mitigative efficacy of a combination of vitamin E, vitamin C and alpha lipoic acid against lindane toxicity in testis has not been reported so far. Therefore, in the present study their role in alleviating the oxidative stress induced by lindane intoxication in testis of mice has been investigated.

Materials and Methods

Chemicals—Lindane (γ -HCH) was obtained from Sigma Chemicals St. Louis, Mo, USA (CAS No. 58-89-9 and purity 97%). Vitamin E, vitamin C, α -lipoic acid, sodium azide, thiobarbituric acid and phenazine methosulphate were obtained from Himedia, India. Dithiobisnitro benzene (DTNB), reduced glutathione and bovine serum albumin were purchased from Sisco Research Laboratories, Mumbai, India. All other chemicals and solvents used were of analytical grade.

Animals and treatment—Male Swiss mice (40), weighing 30 ± 5 g and 8-10 weeks old were procured from Cadila Health Care Institute, Ahmedabad.

Animals were maintained on sterilized rice husk bedding in polypropylene cages and kept at a temperature of about $23 \pm 3^\circ\text{C}$ with 12 ± 1 h L:D cycle. Animals were fed on standard pelletal diet (Pranav Agro, Baroda). Food and water were given *ad libitum*.

Experimental protocol was approved by the Institutional Animal Ethics Committee. Handling of animals was according to the guidelines of Committee for the Purpose of Control and Supervision of Experiments on Animals (CPCSEA), Ministry of Environment and Forests, Govt. of India.

Dose selection—Dose for lindane was selected after conducting pilot experiments in our laboratory. LD₅₀ for lindane was found to be at 60 mg/kg body wt. Considering this aspect, a dose level which may show adverse effect on testis was selected as the dose for the present study. Duration of treatment was based on occupational exposure of workers i.e., for 2 months during active malaria vector control programme. Dose selected for lindane was 40 mg/kg body wt. and duration of treatment was for two months i.e., 60 days. There was no mortality in exposure group during the study.

Doses for antioxidants were calculated keeping the doses prescribed for humans and also in accordance with the previous reports^{33,34}. The combined dose of antioxidants selected was 125 mg/kg body wt. which included vitamin C 50 mg/kg body wt., vitamin E 50 mg/kg body wt. and α -lipoic acid 25 mg/kg body wt. Doses of lindane, vitamin E and lipoic acid were prepared by dissolving in olive oil. Dose of vitamin C was prepared in distilled water.

Experimental protocol—A sub chronic study was done for 60 days and oral route of dose administration was chosen for all treatments. Mice were divided into 4 groups with minimum of 8-10 animals in each group

- Group I: Control (C) group (given olive oil)
- Group II: Lindane (L) group (given 40 mg/kg body wt. dose of lindane dissolved in olive oil)
- Group III: Antioxidants (A) group (given a combined dose of antioxidants at 125 mg/kg body wt.)
- Group IV: Antioxidants and lindane (A+L) group (given combined dose of antioxidants at 125 mg/kg body wt. plus lindane at a dose of 40 mg/kg body wt.).

In group IV, the antioxidants were administered 1 h prior to lindane administration.

Histological preparation—Mice were sacrificed by cervical dislocation at the end of the scheduled period of 60 days and 24 h after the last dose treatment. After dissection both the testis were removed, blotted free off blood, weighed and the left testes was fixed in alcoholic Bouin's fluid. After 18 to 24 h of fixation the testes was further processed for paraffin embedding. Serial sections of 5-7 μm thick were cut using a rotary microtome. Deparaffinized sections were routinely stained with haematoxylin and eosin, examined and photomicrographed.

Biochemical estimation—For biochemical analyses, right testes was washed with ice cold physiological saline and 10% w/v homogenate was prepared in chilled distilled water. Chilled distilled water was used in order to make cytolysis as complete as possible³⁵. The homogenate was centrifuged at $6000 \times g$ for 10 min to obtain the supernatant. Supernatant was diluted 5 times and used for estimating the following biochemical parameters.

Estimation of Lipid Peroxidation (LPO)—The LPO was assayed according to the method of Wilber *et al.*³⁶ by estimating accumulation of peroxidative product, thiobarbituric acid reactive substances (TBARS). Concentration of TBARS was calculated using a molar extinction coefficient of $1.56 \times 10^5/\text{M}$ per cm and the activity of LPO was expressed as nmol TBARS/g tissue.

Estimation of Glutathione (GSH)—GSH was estimated by the method of Moron *et al.*³⁷. GSH on reaction with 5,5-dithiobis-2-nitrobenzoic acid results in the formation of a product that has a maximal absorbance at 412 nm. Reduced GSH was used as standard and the concentration was expressed as mg/gm tissue.

Estimation of Superoxide Dismutase (SOD)—SOD (E. C.1.15.1.1) activity was determined by the method of Kakkar *et al.*³⁸. The assay was based on inhibition of the formation of nicotinamide adenine dinucleotide, phenazine methosulphate and amino blue tetrazolium formazan. One unit of enzyme was expressed as 50% inhibition of NBT (nitroblue tetrazolium) reduction /min/mg protein.

Estimation of Catalase (CAT)—CAT (E.C.1.11.1.6) was determined by the method of Cohen *et al.*³⁹. Enzyme activity is expressed as units (U) of CAT activity/mg protein. One unit of enzyme activity was defined as μmol of H_2O_2 decomposed/min.

Estimation of Glutathione Peroxidase (GPx)—GPx activity was measured by the method of Rotruck *et al.*⁴⁰. Briefly, the reaction mixture contained 0.2 ml of 0.4 M Tris-HCl buffer pH 7.0, 0.1 ml of 10 mM sodium azide, 0.2 ml of tissue homogenate, 0.2 ml glutathione, 0.1 ml of 0.2 mM hydrogen peroxide. The contents were incubated at 37°C for 10 min. The reaction was arrested by 0.4 ml of 10% TCA, and centrifuged. The supernatant was assayed for glutathione content by using Ellmans reagent (19.8 mg of 5,5'-dithiobisnitro benzoic acid (DTNB) in 100 ml of 0.1% sodium nitrate). The activity was expressed as mg of GSH consumed/min/mg protein.

Estimation of Protein—Total protein was estimated by the method of Lowry *et al.*⁴¹ using Folin's reagent, and bovine serum albumin was used as standard. The value of protein content was expressed in mg/100 mg tissue weight.

Statistical Evaluation—Values are Mean \pm SD and the results obtained were analyzed using one-way ANOVA. Inter group comparisons were performed by using the least significance difference (LSD) test. A probability value of $P < 0.05$, 0.01 was considered as statistically significant.

Results

Effect on testis weight

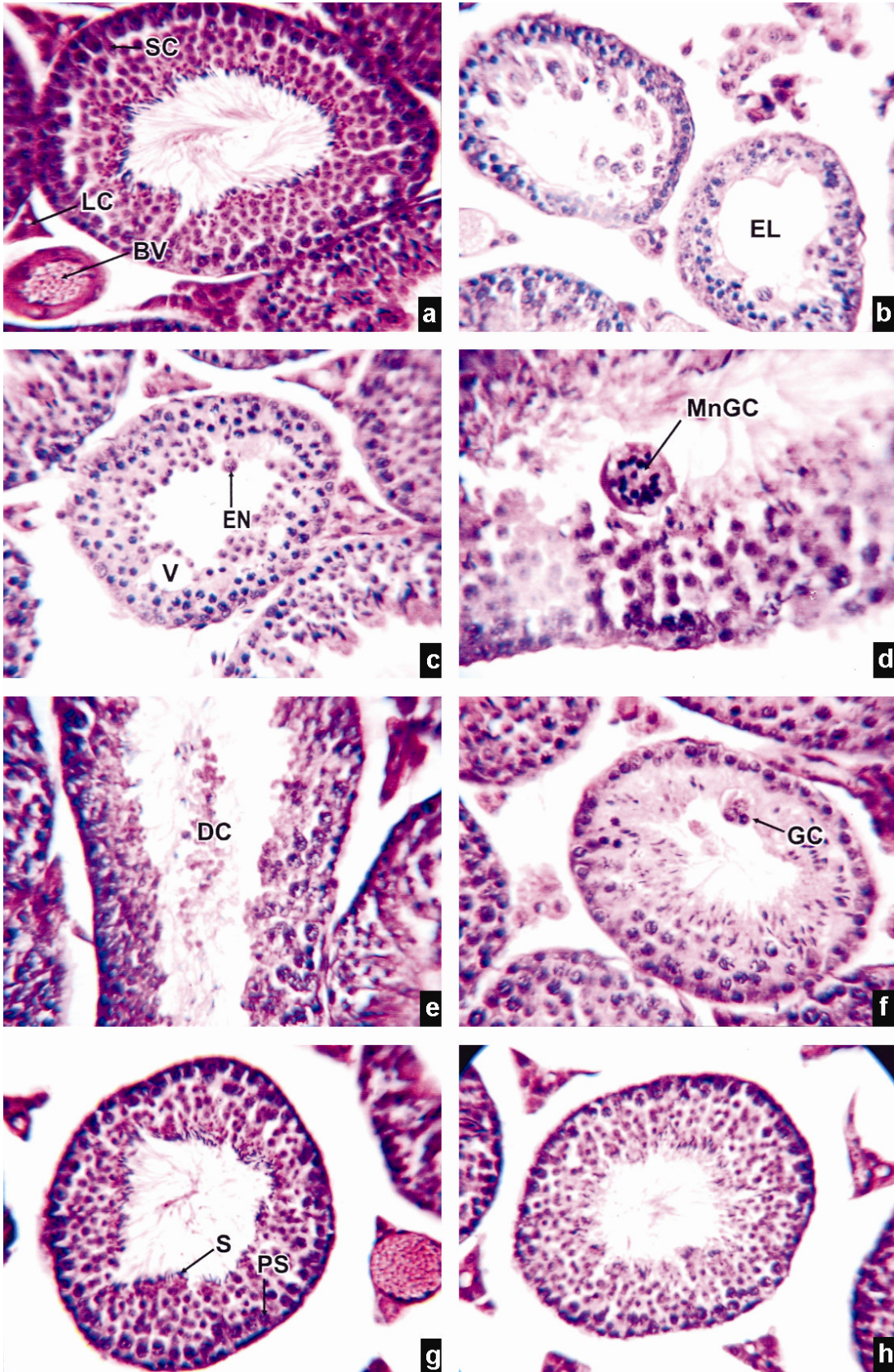
A significant decrease ($P < 0.05$) was observed in the weight of testis after lindane treatment in group L as compared to group C. Pretreatment with antioxidants in group A+L significantly increased ($P < 0.05$) the weight of the testis as compared to group L (Table 1).

Histopathological findings—Histological sections of testis of control group (C) (Fig. 1a) revealed healthy blood vessels (BV) and normal architecture of seminiferous tubules richly populated by normal cells. All the cells involved in spermatogenesis such as

Table 1—Changes in the average weight (g) of both the testis in control (C), lindane treated (L), antioxidant (A) and antioxidant plus lindane treated (A+L) groups

[Values are Mean \pm SD]	
Group	Average weight of both testis (g)
C	0.2233 \pm 0.0103
L	0.2017 \pm 0.0132 ^{a*}
A	0.2467 \pm 0.0081
A+L	0.2217 \pm 0.0098 ^{b*}

** $P < 0.01$ * $P < 0.05$; a: group L compared with group C; b: group A+L compared with group L
C: Control group; L: Lindane treated group; A: Antioxidant group; A+L: Antioxidant + lindane treated group



spermatogonia (PS), spermatocyte, spermatids, spermatozoa (S), and sertoli cells (SC) could be clearly identified in the tubules. The lumen could easily be delineated in almost all the tubules and majority of them were occupied by mature spermatozoa. The myoid and Leydig cells (LC) were present in between the tubules.

Sections of testis from lindane group (L) depicted sparse blood vessels in interstitium. Majority of the seminiferous tubules were shrunken and had a wavy outline. Some of the tubules manifested only spermatogonia and spermatocytes, demarcated by decrease in their number, increased size and darkly stained nuclei (Fig. 1b). The number and characteristic grouping tendency of Leydig cells was reduced. In some tubules, multinucleated giant cells (MnGC) with 15-20 nuclei were seen showing the degree of damage (Fig. 1d). Debris of dead cells (DC) could be seen in the lumen of most of the seminiferous tubules (Fig. 1e). Giant cells (GC) with enlarged nucleus (EN) were seen in the tubules (Figs. 1c and f). The most observable feature was oligozoospermia.

In group A (Fig. 1g) the testis revealed normal structure as observed in group C.

In group A+L (Fig. 1h) sections were quite similar to those of group C and the pathological changes like

MnGC, enlarged lumen, enlarged cells, distorted seminiferous tubules as observed in group L were not seen.

Biochemical findings

Changes in various parameters after different treatment schedules are presented in Table 2.

Effect on LPO—LPO increased significantly ($P<0.01$) in group L as compared to group C. The pretreatment with antioxidants in group A+L significantly decreased the LPO level ($P< 0.01$) as compared to group L.

Effect on GSH—GSH level was lowered significantly ($P<0.01$) in group L in comparison to group C, whereas in group A+L the level increased significantly ($P< 0.05$) than that in the group L.

Effect on SOD—Lindane intoxication significantly decreased the SOD level ($P<0.01$) as compared to group C whereas it increased significantly ($P<0.01$) in the group A+L as compared to group L.

Effect on CAT—Group L showed significantly decreased CAT level ($P < 0.01$) as compared to group C but in group A+L significant increase in the CAT level ($P<0.05$) was observed as compared to group L.

Effect on GPx—In group L level of GPx decreased significantly ($P<0.01$) as compared to group C. The pretreatment with antioxidants in group A+L

Table 2—Changes in various biochemical parameters of control (C), lindane treated (L), antioxidant (A) and antioxidant plus lindane treated (A+L) groups

[Values are Mean ± SD]

Group	LPO (nmol TBARS/g tissue)	GSH (mg/gm tissue)	GPx (mg of GSH consumed /min/mg protein)	SOD (50% inhibition of NBT/min/mg protein)	CAT (µmol of H ₂ O ₂ decomposed /min/mg protein)	Protein (mg/100mg tissue weight)
C	1.3784±0.3769	3.7603±0.6526	11.0644±1.7567	26.7307±4.1358	137.2882±35.7050	61.6237±5.0979
L	2.4118±0.262 ^{a**}	2.4262±0.4762 ^{a**}	5.0743±0.5968 ^{a**}	13.474±1.7503 ^{a**}	58.3430±10.5359 ^{a**}	47.2060±3.9951 ^{a**}
A	1.0131±0.1863	3.2815±0.6113	12.4614±2.7044	28.1750±4.8669	192.5790±58.7621	62.8865±1.6850
A+L	1.4262±0.2474 ^{b**}	3.3778±0.6843 ^{b*}	10.840±3.3376 ^{b**}	21.8968±4.0204 ^{b**}	111.741±27.2155 ^{b*}	54.284±1.7584 ^{b**}

** $P< 0.01$; * $P < 0.05$; a: group L compared with group C; b: group A+L compared with group L

C: Control group; L: Lindane treated group; A: Antioxidant group; A+L: Antioxidant plus lindane treated group; LPO: Lipid Peroxidation; GSH: Glutathione; GPx: Glutathione peroxidase; SOD: Superoxide dismutase; CAT: Catalase

Fig. 1—Histological sections of testis stained by H & E at 400 ×. (a)-Section of testis of control group showing normal seminiferous tubules with all the cells of spermatogenic series. Blood vessels (BV) and Leydig cells (LC) also normal; (b)-Shows shrunken and distorted seminiferous tubules containing only spermatogonia with enlarged lumen (EL). Mass of cells can be seen in the interstitium; (c)-Vacoulation (V) in the seminiferous tubules and giant cells (GC) with enlarged nucleus (EN); (d)-Multinucleated giant cells (MnGC) with 15-20 nuclei; (e)-Dead cells (DC) in the lumen of seminiferous tubules and also reveals oligozoospermia; (f)-Giant cell (GC) with 3 nuclei; (g)-Section of testis from the antioxidant treated group revealing normal features; (h)-Section of testis from antioxidant plus lindane treated group showing features close to normal structure.

significantly increased the GPx level ($P < 0.01$) as compared to group L.

Effect on Protein—Protein content in group L reduced significantly ($P < 0.01$) as compared to group C, whereas the pretreatment with combination of antioxidants in group A+L showed complete restoration of protein ($P < 0.01$) as compared to group L.

Discussion

Marked changes were observed in the histology of testis after lindane treatment for two months. Earlier studies have also shown the occurrence of giant cells⁴² and multinucleated giant cells (MnGC)^{12,43,44} in the lumen of mice as observed in the present study. Such changes may be attributed to failure of cytokinesis and hypertrophy. Vacuolations observed are similar to earlier reports⁴⁵. Lindane affects seminiferous tubules and the number of Leydig cells in interstitium decreased markedly and their tendency to form groups was also reduced in exposed group. Thus, subdued steroid hormone biosynthesis in Leydig cells as reported earlier is supported by the present observation⁴. Dead cells in lumen and the decreased number of germ cells may be due to cytotoxic and apoptotic effect of lindane⁴⁶⁻⁴⁸. Histopathological changes such as atrophy and decreased number of germ cells may be a reason for decreased testicular weights as observed in the present and earlier reports^{22,49}.

Such pathological changes are due to oxidative stress induced by lindane. Induction of oxidative stress by lindane has been demonstrated in many tissues such as liver⁵⁰, heart⁵¹, blood^{52,53}, erythrocytes⁵⁴, brain^{33,34,55}, epididymis and epididymis sperm⁵⁶ and testis²¹⁻²³.

Results of present study demonstrated the increase in lipid peroxidation (LPO) similar to earlier reports^{22,23}. LPO is a characteristic manifestation of oxidative damage caused in cells and tissues⁵⁷. Increase in LPO results owing to increase in ROS or alternatively lindane may inhibit antioxidant molecules and antioxidant enzymes which is supported by the findings that lindane reduces antioxidant molecules and antioxidant enzymes^{22,23,33,53}.

Superoxide radicals are deleterious to PUFA (Poly Unsaturated Fatty Acids) and structural proteins of plasma membrane and their disposition is facilitated by SOD⁵⁸. Similar to earlier reports, results of the present study also show a decrease in SOD level in the treated group. In all such cases the main culprit being superoxide radicals^{22,49,59}.

A decrease in SOD activity favors the accumulation of superoxide radicals, which in turn inhibit CAT⁶⁰, thus decreased CAT activity in the lindane treated group is similar to earlier findings^{22,49,59}. The decreased CAT activity results in the augmentation of H₂O₂ generation⁶¹. H₂O₂ generated needs to be rapidly eliminated to prevent the induction of oxidative damage to lipids, proteins and DNA⁶¹. The elimination of H₂O₂ is either effected by CAT or GPx, with the latter playing predominating role in the testis⁶².

GPx is involved in catalyzing the reduction of H₂O₂ at the expense of reduced GSH^{63,64}. The level of GPx in the exposed group was lowered which can be attributed to either increased H₂O₂ generation or decreased GSH concentration⁶⁵.

Decrease in GSH level as observed in the present study may be due to increased utilization of GSH for metabolism of lipid hydroperoxides by GPx or interaction of GSH with free radicals. Similar analogy is being also drawn in the earlier reports^{66,67}. Perturbation of GSH status of biological system can lead to serious consequences⁶⁸. Increased generation of superoxide radicals in turn lead to oxidation and depletion of GSH⁶⁹ with lipid peroxidative response.

Histoarchitectural changes as seen in this study get corroborated by the significant changes seen in the enzymes of antioxidant defense system as well as LPO. Therefore, increase in LPO is the reflection of damage caused to the membranous structures. Moreover, overproduction of ROS may further damage vital components of cell, like nucleic acids and proteins which further lead to oligozoospermia and abnormal spermatozoa.

All the histopathological changes and biochemical alterations were ameliorated after the treatment with combination of vitamin C, vitamin E and α -lipoic acid. Vitamin E is the most potent lipid soluble peroxyl radical scavenger that limits lipid peroxidation initiated by free radicals in the lipid of biological membranes^{70,71} and in testicular microsomes and mitochondria⁷². It also reverses the detrimental effects of oxidative stress on testicular function mediated by different agents⁷³⁻⁷⁶.

Vitamin C is a water soluble antioxidant which inhibits the peroxidation of membrane phospholipids and acts as a scavenger of free radicals⁷⁷. It also regenerates α -tocopherol (vitamin E) from the α -tocopheroxyl radical^{78,79} and moreover as compared to vitamin E, it is believed to cross the blood testis barrier efficiently. Thus, vitamin C was chosen to

improve the functioning of vitamin E. It also counteracts testicular oxidative stress induced by various agents^{36,42,75,80}.

α -Lipoic Acid (ALA) is known to be a very potent antioxidant⁸¹. Within the body ALA is often reduced to dihydrolipoic acid (DHLA) and both ALA and DHLA are the most powerful biological antioxidant systems⁸². ALA has a further positive effect as it is able to re-synthesize vitamins C, E, and glutathione, and therefore enhances the effectiveness of this antioxidant system^{83,84}.

α -Lipoic acid also causes an increase in intracellular GSH *in vitro* as well as *in vivo*⁸⁵. A number of studies show that lipoic acid inhibits the oxidative damage^{86,87}.

The beneficial effects of various combinations of antioxidants against toxicity in testis in rats have been reported⁸⁸ the combination showed more profound effect as compared to their individual administration⁸⁹. However, the effect of combination of antioxidants studied in the present investigation on lindane toxicity has not been reported so far.

Moreover, based on the findings of the present study, it may be concluded that the combination of antioxidants taken play a vital role in mitigating the various pathological and biochemical changes in testis caused due to lindane. Furthermore, it is suggested that the given combination of antioxidants acts synergistically in reducing lindane induced testicular dysfunction.

References

- Chiras D, Principles of Toxicology and Risk Assessment, in : *Environmental Science* 8th ed.(Jones and Barlett Learning, Sudbury, MA) 2010, 380.
- Kojima S, Ishihara N, Hirukawa H & Kiyozumi M, Effect of N-benzyl-D-glucamine dithiocarbamate on lipid peroxidation in testes of rats treated with cadmium, *Res Commun Chem Pathol Pharmacol*, 67 (1990) 259.
- Peltola V, Montyla E, Hutaniemi I & Ahutupa M, Lipid peroxidation and antioxidant enzyme activities in the testis after cigarette smoke inhalation or administration of polychlorinated biphenyls or polychlorinated naphthalenes, *J Androl*, 15 (1994) 353.
- Shivanandappa T & Krishnakumari M K, Hexachlorocyclohexane-induced testicular dysfunction in rats, *Acta Pharmacol Toxicol*, 52 (1983) 12.
- Walsh L P & Stocco D M, Effects of lindane on steroidogenesis and steroidogenic acute regulatory protein expression, *Biol Reprod*, 63 (2000) 1024.
- Wauchope R D, Buttler T M, Hornsby A G, Augustijn-Beckers P W & Burt J P, The SCS/ARS/CES pesticide properties database of environmental decision making of, *Rev Environ Contam Toxicol*, 123 (1992) 1.
- Srinivasan K & Radhakrishnamurty R, Studies on the distribution of b- and g-isomers of hexachlorocyclohexane in rat tissues, *J Environ Sci Health B*, 18 (1983) 401.
- Sauviat M P & Pages N, Cardiotoxicity of lindane: A gamma isomer of hexachlorohexane, *J Soc Biol*, 196 (2002) 339.
- WHO Report, International programme on chemical safety, In: Health and Safety Guide-54 Lindane, WHO, Geneva, (1991) 14.
- Dalsenter P R, Faqi A S, Webb J, Merker H J & Chahoud I, Reproductive toxicity and tissue concentrations of lindane in adult male rats, *Hum Exp Toxicol*, 15 (1996) 406.
- Suwalsky M, Villena F, Marcus D & Ronco A M, Plasma absorption and ultrastructural changes of rat testicular cells induced by lindane, *Hum Exp Toxicol*, 19 (2000) 529.
- Chowdhury A R, Venkatakrishna-Bhatt H & Gautam A K, Testicular changes of rats under lindane treatment, *Bull Environ Contam Toxicol*, 38 (1987) 154.
- Chowdhury A R & Gautam A K, Steroidogenic impairment after lindane treatment in male rats, *Sangyo Ika Daigaku Zasshi*, 16 (1994) 145.
- Prasad A K, Pant N, Srivastava S C, Kumar R & Srivastava S P, Effect of dermal application of hexachlorocyclohexane (HCH) on male reproductive system of rat, *Hum Exp Toxicol*, 14 (1995) 484.
- Iwasaki A & Gagnon C, Formation of reactive oxygen species in spermatozoa of infertile patients, *Fertil Steril*, 57 (1992) 409.
- Shen H & Ong C, Detection of oxidative DNA damage in human sperm and its association with sperm function and male infertility, *Free Radic Med Biol*, 28 (2000) 529.
- Urata K, Narahara H, Tanaka Y, Egashira T, Takayama F & Miyakawa I, Effect of endotoxin-induced reactive oxygen species on sperm motility, *Fertil Steril*, 76 (2001)163.
- Aitken R J, A free radical theory of male infertility, *Reprod Fertil Dev*, 6 (1994) 19.
- Aitken R J & Krausz C, Oxidative stress, DNA damage and the Y chromosome, *Reproduction*, 122 (2001) 497.
- Saleh R A & Agrawal A, Oxidative stress and male infertility: From research bench to clinical practice, *J Androl*, 23 (2002) 737.
- Samanta L & Chainy G B, Comparison of Hexachlorocyclohexane induced oxidative stress in the testis of immature and adult rats, *Comp Biochem Physiol*, 118 (1997) 319.
- Samanta L & Chainy G B, Response of testicular antioxidant enzymes to hexachlorocyclohexane is species specific, *Asian J Androl* 4 (2002) 191.
- Sharma P & Singh R, Protective Role of Curcumin on Lindane Induced Reproductive Toxicity in Male Wistar Rats, *Bull Environ Contam Toxicol*, 84 (2010) 378.
- Diplock A T, Antioxidants and disease prevention, *Mol Aspects Med*, 15 (1994) 293.
- Storey B T, Biochemistry of the induction and prevention of lipoperoxidative damage in human spermatozoa, *Mol Hum Reprod*, 3 (1997) 203.
- Bagchi K & Puri S, Free radicals and antioxidants in health and disease, *Eastern Mediterranean Health Journal*, 4 (1998) 350.
- Davies K, Oxidative stress: the paradox of aerobic life, *Biochem Soc Symp*, 61 (1995) 1.

- 28 Slater T F & Swayer B C, The effect of carbon tetra chloride on rat liver microsomes during first hour of poisoning *in vivo* and the modifying action of promethazine, *Biochem J*, 111 (1979) 317.
- 29 Vidyasagar J N, Karunakar M S, Reddy K, Rajnarayana T, Surender & Krishna D R, Oxidative stress and antioxidant status in acute organophosphorus insecticide poisoning, *Indian J Pharmacol*, 36 (2004) 76.
- 30 Tiwari R K, Bandyopadhyay S K & Chatterjee G C, Protective effect of L ascorbic acid in lindane intoxicated rats, *Acta Vitaminol Enzymol*, 4 (1982) 215.
- 31 Podstawka V, Grabarezyk M & Kopeeszlezak J, Vitamin E protects human leucocytes against toxic effect of lindane *in vitro*, *Mater Med Pol*, 23 (1991) 285.
- 32 Srivastava A & Shivanandappa T, Hexachlorocyclohexane differentially alters the antioxidant status of the brain regions in rat, *Toxicol*, 214 (2005) 123.
- 33 Bano M & Bhatt D K, Neuroprotective Role of a Novel Combination of Certain Antioxidants on Lindane (γ -HCH) Induced Toxicity in Cerebrum of Mice, *Research Journal of Agriculture and Biological Sciences*, 3 (2007) 664.
- 34 Bano M & Bhatt D K, Ameliorative effect of a combination of vitamin E, vitamin C, alpha-lipoic acid and stilbene resveratrol on lindane induced toxicity in mice olfactory lobe and cerebrum, *Indian J Exp Biol*, 48 (2010) 150.
- 35 Schneider W C & Potter V R, The assay of animal tissues for respiratory enzymes II. Succinic dehydrogenase and cytochrome oxidase, *J Biol Chem*, 149 (1943) 217.
- 36 Wilber K M, Baerheim F & Shapiro O W, The thiobarbituric acid reagent as a test for the oxidation of unsaturated fatty acid by various reagents, *Arch Biochem Biophys*, 24 (1949) 304.
- 37 Moron M A, Depierre J W & Mannervick B, Levels of Glutathione, Glutathione reductase, Glutathione S-Transferase activities in rat lung and liver, *Biochem Biophys Acta*, 582 (1979) 67.
- 38 Kakkar P, Das B & Viswanathan P N, A modified spectrophotometric assay of superoxide dismutase, *Indian J Biochem Biophys*, 21 (1984) 130.
- 39 Cohen G, Dembiec D & Marcus J, Measurement of catalase activity in tissue extracts, *Analytical Biochemistry*, 34 (1970) 30.
- 40 Rotruck J T, Pope A L, Ganther H E & Swanson A B, Selenium: Biochemical roles as a component of glutathione peroxidase, *Science*, 179 (1973) 588.
- 41 Lowry O H, Roesborough M J, Farr A L & Randall R J, Protein measurement with Folin-Phenol reagent, *J Biol Chem*, 193 (1951) 265.
- 42 Chinoy N J, Sorathia H P, Jhala D D, Fluoride+Aluminium induced toxicity in mice testis with giant cells and its reversal by vitamin C, *Fluoride*, 38 (2005) 109.
- 43 Dikshith T S S & Datta K K, Pathologic changes induced by pesticides in the testes and liver of rats, *Exp Path*, 7 (1972b) 309.
- 44 Nigam S K, Lakkad B C, Karnik A B, Thakore K N, Bhatt D K, Arvinda Babu K & Kashyap S K, Effect of hexachlorocyclohexane feeding on testicular tissues of pure inbred Swiss mice, *Bull Environ Contam Toxicol*, 23 (1979) 431.
- 45 Eweka A O & Om'Iniabohs F A E, Histological studies of the effects of monosodium glutamate on the testis of adult Wistar rats, *The Internet J of Urology*, 5 (2008) 2.
- 46 Saradha B, Vaithinathan S & Mathur P P, Lindane induces testicular apoptosis in adult Wistar rats through the involvement of Fas-FasL and mitochondria-dependent pathways, *Toxicology*, 255 (2009) 131.
- 47 Yuksel H, Karadas E, Keles H & Demirel H H, Effects of hexachlorocyclohexane (γ -isomer, lindane) intoxication on the proliferation and apoptosis in rat testes, *Acta Vet Brno*, 78 (2009) 615.
- 48 Sala G L, Farini D & Felici M D, Proapoptotic effects of lindane on mouse primordial germ cells, *Toxicological Sciences*, 108 (2009) 445.
- 49 Sujatha R, Chitra K C, Latchoumycandane C & Mathur P P, Effect of lindane on testicular antioxidant system and steroidogenic enzymes in adult rats, *Asian J Androl*, 3 (2001) 135.
- 50 Videla L A, Barros S B & Janqueria V B, Lindane induced liver oxidative stress, *Free Radical Biol Med*, 9 (1990) 69.
- 51 Ananya R S, Subeena D A, Kumar D T & Kumar S M, Oxidative stress and histopathological changes in the heart following oral lindane administration in rats, *Med Sci Monit*, 11 (2005) 325.
- 52 Banerjee B D, Seth V, Bhattacharya A, Pastha S T & Chakraborty A K, Biochemical effects of some pesticides on lipid peroxidation and free radical scavengers, *Toxicol Lett*, 107 (1999) 33.
- 53 Fidan A F, Cigerci I H, Sozbilir N B, Kucukkurt I, Yuksel H & Keles H, The effects of the dose-dependent hexachlorocyclohexane (Lindane) on blood and tissue antioxidant defense systems, lipid peroxidation and histopathological changes in rats, *J Anim Vet Adv*, 7 (2008) 1480.
- 54 Radosavljevic T, Mladenovic D, Jakovljevic V, Vucvi D, Ras-Markovi A, Hrnci D, Djuric D & Stanojlovic O, Oxidative stress in liver and red blood cells in acute lindane toxicity in rats, *Human & Experimental Toxicology*, 28 (2009) 747.
- 55 Bist R & Bhatt D K, The evaluation of effect of alpha-lipoic acid and vitamin E on the lipid peroxidation, gamma-amino butyric acid and serotonin level in the brain of mice (*Mus Musculus*) acutely intoxicated with lindane, *J Neurol Sci*, 276 (2009) 99.
- 56 Chitra K C, Sujatha R, Latchoumycandane C & Mathur P P, Effect of lindane on antioxidant enzymes in epididymis and epididymal sperm of adult rats, *Asian J Androl*, 3 (2001) 205.
- 57 Esterbauer H, Schaur R J & Zollner H, Chemistry and biochemistry of 4-hydroxynoneal, malonaldehyde and related aldehydes, *Free Radical Biol Med*, 11 (1991) 81.
- 58 McDonald J R, Bengel E M & Repine A J E, Alveolar macrophage antioxidant prevents hydrogen peroxide – mediated lung damage, *Am Rev Respir Dis*, 143 (1991) 1088.
- 59 Saradha B, Vaithinathan S & Mathur P P, Single exposure to low dose of lindane causestransient decrease in testicular steroidogenesis in adult male Wistar rats, *Toxicology*, 244 (2008) 199.
- 60 Kono Y & Fridovich I, Superoxide radical inhibits catalase, *J Biol Chem*, 257 (1982) 5751.
- 61 Aitken R J & Roman S D, Antioxidant systems and oxidative stress in testes, in *Molecular Mechanisms in Spermatogenesis*, (Landes Bioscience and Springer Science+Business Media), 2008, 154.

- 62 Peltola V, Huhtaniemi I & Ahotupa M, Antioxidant enzyme activity in maturing rat testis, *J Androl*, 13 (1992) 450.
- 63 Grazioli V, Schiavo R, Casari E, Marzatico F, Baena R R & Gaetani P, Antioxidant enzymatic activities and lipid peroxidation in cultured human chondrocytes from vertebral plate cartilage, *FEBS Lett*, 431 (1998) 149.
- 64 Sigalov A B & Stern L J, Enzymatic repair of oxidative damage to human apolipoprotein A-I, *FEBS Lett*, 433 (1998) 196.
- 65 Scibior D, Skrzycki M, Podsiad M & Czeczot H, Glutathione level and glutathione-dependent enzyme activities in blood serum of patients with gastrointestinal tract tumors, *Clin Biochem*, 41 (2008) 852.
- 66 Flohe L, Glutathione peroxidase brought into focus. In: WA Pryor, Editor. Free radicals in biology (Academic Press, New York) 1982, 233.
- 67 Portig J, Kraus P, Stein K, Koransky W, Noack G, Gross B, Sodomann S, Glutathione conjugate formation from hexachloro-cyclohexane and pentachlorocyclohexane by rat liver *in vitro*, *Xenobiotica*, 9 (1979) 353.
- 68 Campos R, Garrido A, Guerra R & Valenzuela A, Silybin dihemisuccinate protects against glutathione depletion and lipid peroxidation induced by acetaminophen on rat liver, *Planta Med*, 55 (1989) 417.
- 69 Reed D, Glutathione: Toxicological implications, *Annu Rev Pharmacol Toxicol*, 30 (1990) 603.
- 70 Burton G W, Joyce A & Ingold K V, Is vitamin E the only lipid soluble, chain breaking antioxidant in human blood plasma and erythrocyte membrane? *Achieves of Biochemistry and Biophysics*, 221 (1983) 281.
- 71 Sandy S, Dimonte D & Smith M T, Relationship between intracellular vitamin E, lipid peroxidation and chemical toxicity in hepatocytes, *Toxicol Appl Pharmacol*, 93 (1998) 288.
- 72 Gavazza M B & Catala A, The effect of alpha-tocopherol on lipid peroxidation of microsomes and mitochondria from rat testis, *Prostaglandins Leukot Essent Fatty Acids*, 74 (2006) 247.
- 73 Verma R J & Nair A, Ameliorative effect of vitamin E on aflatoxin induced lipid peroxidation in the testis of mice, *Asian J Androl*, 3 (2001) 217.
- 74 Latchoumycandane C & Mathur P P, Effects of vitamin E on reactive oxygen species-mediated 2,3,7,8-tetrachloro-dibenzo-p-dioxin toxicity in rat testis, *J Appl Toxicol*, 22 (2002) 345.
- 75 Sen Gupta R, Sen Gupta E, Dhakal B K, Thakur A R & Ahn J, Vitamin C and vitamin E protect the rat testes from cadmium-induced reactive oxygen species, *Mol Cells*, 17 (2004) 132.
- 76 Jedlinska-Krakowska M, Bomba G *et al*, Impact of oxidative stress and supplementation with vitamins E and C on testis morphology in rats, *J Reprod Dev*, 52 (2006) 203.
- 77 Frei B, England L & Ames B N, Ascorbate is an outstanding antioxidant in human blood plasma, *Proc Nat Acad Sci*, 86 (1989) 6377.
- 78 Bowry V W, Mohr D, Cleary J & Stocker R, Prevention of tocopherol-mediated peroxidation in ubiquinol-10-free human low density lipoprotein, *J Biol Chem*, 270 (1995) 5756.
- 79 Packer L, Vitamin C and redox cycling antioxidants, in *Vitamin C in health and disease*, (Packer L, Fuchs J, eds, New York: Marcel Dekker Inc), 1997, 95.
- 80 Chang S I, Jin B, Youn P *et al*, Arsenic-induced toxicity and the protective role of ascorbic acid in mouse testis, *Toxicol Appl Pharmacol*, 218 (2007) 196.
- 81 Midaoui A & De Champlain J, Prevention of hypertension, insulin resistance and oxidative stress by alpha-lipoic acid, *Hypertension*, 39 (2002) 303.
- 82 Moini H, Tirosh O, Park Y C, Cho k -J & Packer L, R-alpha-lipoic acid action on cell redox status, the insulin receptor, and glucose uptake in 3T3-L1 adipocytes, *Arch Biochem Biophys*, 397 (2002) 384.
- 83 Kagan W, Kuhlinski B, Ruhlmann C & Plotz C, Recycling of Vitamin E in human low lipoproteins, *J Lipid Res*, 33 (1992) 385.
- 84 Biewenga G P, Haenen G R M M & Bast A, The pharmacology of the antioxidant lipoic acid, *Gen Pharmacol*, 29 (1997) 315.
- 85 Busse E, Zimmer G, Schopohl B & Kornhuber B, Influence of alpha-lipoic acid on intracellular glutathione *in vitro* and *in vivo*, *Arzneim-Forsch*, 42 (1992) 829.
- 86 Selvakumar E, Prahalathan C, Sudharsan P T & Varalakshmi P, Protective effect of lipoic acid on cyclophosphamide-induced testicular toxicity, *Clinica Chimica Acta*, 367 (2006) 114.
- 87 Prahalathan C, Selvakumar E & Varalakshmi P, Protective effect of lipoic acid on adriamycin-induced testicular toxicity, *Clinica Chimica Acta*, 360 (2005) 160.
- 88 Koyuturk M, Yanardag R, Bolkent S & Tunali S, Influence of combined antioxidants against cadmium induced testicular damage, *Environ Toxicol Pharmacol*, 21 (2006) 235.
- 89 Kara H, Cevik A, Konar V, Dayangac A & Yilmaz M, Protective effects of antioxidants against cadmium-induced oxidative damage in rat testes, *Biol Trace Elem Res*, 120 (2007) 205.