

Wound healing activity of *Carica papaya* L. in experimentally induced diabetic rats

B Shivananda Nayak¹, Lexley Pinto Pereira² & Dale Maharaj³

Departments of ¹Preclinical Sciences, ²Paraclinical Sciences, and ³Clinical Surgical Sciences,
Faculty of Medical Sciences, The University of the West Indies, St. Augustine, Trinidad

Received 28 September 2006; revised 16 April 2007

The aqueous extract of *C. papaya* fruit (100 mg kg⁻¹ day⁻¹ for 10 days) was evaluated for its wound healing activity in streptozotocin-induced diabetic rats using excision and dead space wound models. Extract-treated animals exhibited 77% reduction in the wound area when compared to controls which was 59%. The extract treated wounds were found to epithelize faster as compared to controls. The wet and dry granulation tissue weight and hydroxyproline content increased significantly when compared to controls. The extract exhibited antimicrobial activity against the five organisms tested. *Carica papaya* promotes significant wound healing in diabetic rats and further evaluation of this activity in humans is suggested.

Keywords: Diabetic, Excision wound, Hydroxyproline, Incision wound

Diabetic wounds are slow, non-healing wounds that can persist for weeks despite adequate and appropriate care. Such wounds are difficult and tough to manage¹. Though the exact pathogenesis of poor wound healing in diabetic wounds is not clearly understood, evidence from studies involving both human and animal models reveal several abnormalities in the various phases of the wound healing process^{2,3}. Some patients attending the Diabetic Wound Care clinic of one of the authors (DM) who showed satisfactory healing attributed the healing to the latex of *C. papaya* applied to their wounds, which prompted this investigation.

The use of *Carica papaya* L. (Caricaceae) in traditional medicine relies on papain, the active principle which exerts an ulcer protective effect⁴. The *C. papaya* possesses antimicrobial⁵, antioxidant⁶ and anti-inflammatory activities⁷. It is reported to heal chronic ulcers as well⁸. The present study has been undertaken to examine the wound healing activity of the fruit extract of *C. papaya* in experimentally induced excision and dead space wounds in diabetic rats.

Materials and Methods

Preparation of fruit extract—Unripe fruits of *C. papaya* were collected locally. The extract was prepared according to the method explained by Mahmood *et al.*⁹. The fruit was cleaned with distilled water and the outer green thin layer was peeled and discarded. The underlying epicarp was peeled and 200 g of it was blended with 50 ml of distilled water to a fine texture form using a blender. The mixture was filtered using a fine muslin cloth. The step was followed by rotor vaporized to remove the water. Then the filtrate was oven-dried at 40°C. The dried extract was used for the study.

An acute toxicity study was conducted for the extract by the stair-case method¹⁰. The animals were provided orally with increasing doses (1, 2, 4, and 8 g/kg body weight) of the extract. The toxicity was assessed by mortality and behavior changes of the rats.

Animals—The study was approved by the Ethics Committee for animal experimentation (AHC06/07/1), The Faculty of Medical Sciences, The University of the West Indies, St. Augustine, Trinidad. Healthy inbred Sprague Dawley male rats weighing 200-250 g were individually housed and maintained on normal food and water *ad libitum*. Animals were periodically weighed before and after the experiment. Animals were closely observed for

any infection and if those showing signs of infection were excluded from the study and replaced. The excision and dead space wound models were used to evaluate the wound healing activity of *C. papaya* extract. The animals were randomly distributed into five groups of 6 each in excision and four groups in dead space wound models.

Induction of diabetes—Animals of groups 3, 4 and 5 were weighed and their fasting blood glucose levels were determined before inducing diabetes. The animals were then injected with a single dose of streptozotocin (STZ, 50 mg/kg, Sigma) in cold 0.1 M citrate buffer, pH 4.5 (freshly prepared) in the tail vein to induce diabetes. Control animals were injected with 0.1 M citrate buffer. Fasting blood glucose was measured three days later to confirm the diabetic status of the animals. For blood glucose measurements blood was drawn from the tail vein.

Excision wound model—Rats were inflicted with excision wounds according to the method of Morton and Malone¹¹. Animals were anaesthetized with 1 ml of intravenous ketamine hydrochloride (120 mg/kg body weight) and shaved on both sides of the back with an electric clipper. The area of the wound to be created was outlined on the back of the animals with methylene blue using a circular stainless steel stencil. A full thickness excision wound of circular area 300 mm² and 2 mm in depth was created along the markings. The entire wound was left open. Animals were closely observed for any infection and those which showed signs of infection were separated, excluded from the study and replaced. Animals were divided into five groups of 6 each. The normal controls (group 1) were applied with vaseline, experimental controls (group 2) were applied the extract, diabetic controls (group 3) were applied with vaseline, diabetic experimental rats (group 4) were applied with the extract and the positive controls received an application of mupirocin ointment (group 5). The treatment was done topically in all the cases. The extract was applied at a dose of 100 mg kg⁻¹ day⁻¹ for 10 days. Wound areas were measured on days 1, 5 and 11 for all the groups using a transparency sheet and a permanent marker. Recordings of the wound areas were measured on graph paper. The day of eschar falling, after wounding, without any residual raw wound was considered as the period of epithelialization.

Dead space wound model—Dead space wounds were inflicted by implanting sterile cotton pellets (10

mg each), one on either side in the groin and axilla on the ventral surface of each rat by the technique of D'Arcy *et al.* as described by Turner¹². The animals were divided into four groups of 6 each. The normal controls (group 1) were provided plain water orally, experimental controls (group 2) were given the extract orally in a dose of 100 mg kg⁻¹ day⁻¹ for 10 days, diabetic controls (group 3) were given plain water orally and diabetic experimental rats (group 4) were given extract orally at a dose of 100 mg kg⁻¹ day⁻¹ for 10 days. Since an average rat consumes 110 ml of water/kg/day, 100 mg of the fruit extract was dissolved in 100 ml of drinking water. On the 10th post-wounding day, the granulation tissue formed on the implanted cotton pellets was carefully removed under anaesthesia. After noting the wet weight of the granulation tissue, the tissue was dried at 60°C for 12 hr, and the dry granulation tissue weight was recorded. To the dried tissue 5 ml 6N HCl was added and kept at 110°C for 24 hr. The neutralized acid hydrolysate of the dry tissue was used for the determination of hydroxyproline¹³. Additional piece of wet granulation tissue was preserved in 10% formalin for histological studies.

Antimicrobial activity—*Pseudomonas aeruginosa*, *Proteus mirabilis*, *Enterobacter agglomerans* and *Staphylococcus aureus* were the organisms tested. The bacterial strains were obtained from fresh colonies grown on Mac Conkey blood agar plates. Sensitivity testing was done using Muller Hinton Agar plates. Known volume of bacterial suspension was transferred to each microplate well. Ethanol extract (10µl) of *C. papaya* was added to the microplate wells and incubated at 35°-37°C for 18-20 hr. Results were determined by visual inspection of zones of growth inhibition.

Statistical analysis—The means of wound area measurements between groups at different time intervals were compared using one-way ANOVA, followed by Tukey's post-hoc tests. One-way ANOVA was used to examine the mean differences in wound healing between the groups in incision and dead space wound models. Data were analyzed using the SPSS (Version 12.0, Chicago, USA) and *P* value was set < 0.05 for all analyses.

Results

In acute toxicity studies, the extract in doses up to 4 g/kg body weight did not produce any signs of toxicity and mortality. The animals were physically

active and were consuming food and water in a regular way. No abnormal behavior was noticed.

Significant increase in the wound healing activity was observed in fruit extract treated rats. In excision wound model, animals of groups 2 and 4 showed a decrease in the epithelialization period and increased percentage of wound contraction when compared with the animals of groups 1, 3 and 5 (Table 1). On day 11 the extract-treated animals (groups 2 and 4) showed wound contraction by 77% compared with 59% in wounds of the control groups (groups 1 and 3) ($P < 0.001$). The wound contraction results of extract-treated animals were comparable with positive controls (73%).

In the dead space wound model (Table 2), the extract-treated animals in groups 2 and 4 showed significantly higher levels of hydroxyproline compared with animals in the normal and diabetic control groups ($P < 0.001$). A significant increase was also observed in the dry and wet weight of the granulation tissue in the animals treated with the extract ($P < 0.001$). Overall the weights of the animals did not differ for any of the study groups.

In animals that did not receive the fruit extract treatment, the wounds appeared to be hard and crusty with undermined margins and were generally unclean with a biofilm glaze on the surface (Figs 1 and 3). In contrast the wounds in the animals treated with the extract were clean, and showed bright red healthy granulation tissue. (Figs 2 and 4). The wounds treated

with mupirocin showed the healthy granulation tissue (Fig. 5).

The extract showed antimicrobial activity against selected organisms viz. *Pseudomonas aeruginosa*, *Proteus mirabilis*, *Enterobacter agglomerans*, and *Staphylococcus aureus*

Discussion

Wound healing is characterized by three stages viz, inflammation, proliferation, and remodeling. The proliferative phase typically demonstrates angiogenesis, collagen deposition, granulation tissue formation, epithelialisation and wound contraction. In angiogenesis, new blood vessels grow from endothelial cells. In fibroplasia and granulation tissue formation, fibroblasts grow and form a new provisional extracellular matrix by excreting collagen and fibronectin. In epithelialization, epithelial cells crawl across the wound bed to cover it. Fibronectin the major glycoprotein secreted by fibroblasts has important functions of chemo-attraction for macrophages, fibroblasts and endothelial cells, promoting re-epithelialisation and acting as a transduction agent in wound contraction. Wound contraction occurs by myofibroblasts, which establish a grip on the wound edges bringing them in apposition.

Wound healing deficits in diabetes are diverse, multifactorial, complex and inter related¹⁴. This defect is believed to be caused by impaired blood flow and oxygen release from increased blood sugar, decreased

Table 1—Wound healing activity of the *C. papaya* in streptozotocin induced rats (excision wound model)

[Values are mean ± SE from 6 animals in each group]

Parameter	Group 1	Group 2	Group 3	Group 4	Group 5
Wound area (mm ²):					
Days 1	187.1 ± 0.33	186.8 ± 0.49	189.8 ± 0.30	190.8 ± 0.21	189.33 ± .16
Day 5	136.3 ± 0.2(27%)	130.1 ± 0.0(30%)	146.5 ± 0.22(22%)	132.1 ± 0.2(30%)*	164.30 ± 0.21(13%)
Day 11	55.5 ± 0.2 (59%)	32.0 ± 0.25(76%)	60.5 ± 0.2 (59%)	29.6 ± 0.2(77%)**	43.5 ± 0.22 (73%)
Epithelialization (days)	18.1 ± 0.16	14.3 ± 0.21	19.0 ± 0.0	15.1 ± 0.16	15.5 ± 0.2

P values: * < 0.05; ** < 0.001

Inter-group comparisons were made using one way ANOVA followed by Tukey’s post-hoc tests.

Group 1- Normal control, Group 2- Normal experimental, Group 3- Diabetic control, Group 4- Diabetic experimental and Group 5- Positive control.

Table 2—Wound healing activity of the *C. papaya* in streptozotocin induced rats (dead space wound model)

[Values are mean ± SE from 6 animals in each group]

Parameter	Group 1	Group 2	Group 3	Group 4
Wet granulation weight (mg/100 g rat)	102.5 ± 0.22*	153.1 ± 0.16	90.50 ± 0.22	165.6 ± 0.21
Dry granulation weight (mg/100 g rat)	31.50 ± 0.22	45.10 ± 0.16	28.60 ± 0.21	42.30 ± 0.21**
Hydroxyproline (mg/g tissue)	55.20 ± 0.22	93.5 ± 0.22	67.50 ± 0.22	91.00 ± 0.44**

Inter-group comparisons were made using ANOVA.

Other details are same as in Table 1

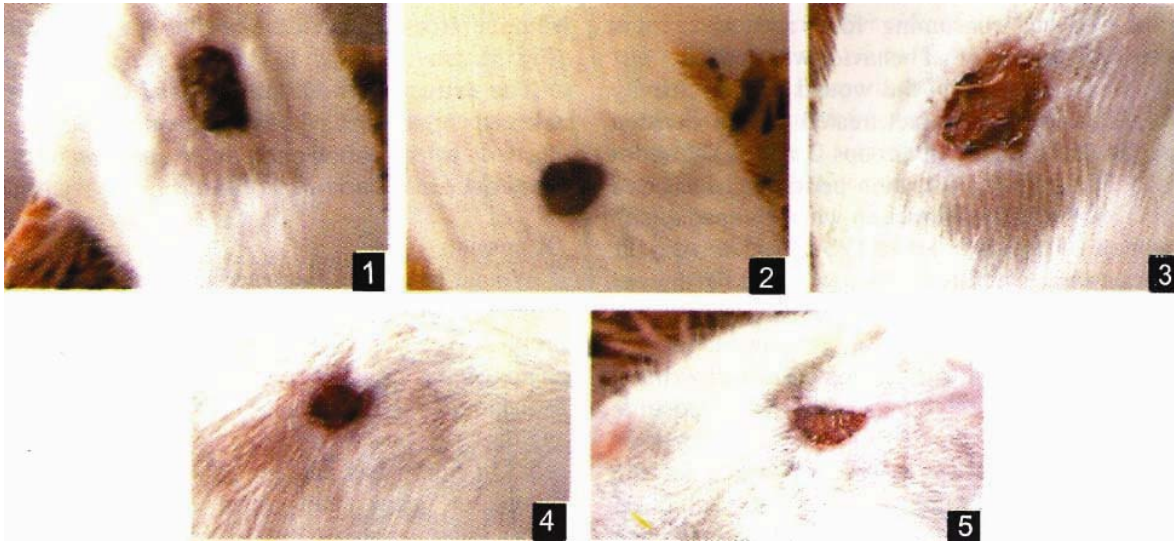


Fig. 1-5:1—Normal control with vaseline treatment (day 11). 2—Normal experimental treated with extract (day 11). 3—Diabetic control with vaseline treatment (Day 11). 4—Diabetic experimental treated with extract (day 11). 5—Mupirocin treated (day 11).

collagen and fibronectin synthesis from protein malnutrition, impaired local immune and cell defenses, and decreased anabolic activity with decreased insulin and growth hormone. Collagen, fibrin and keratin accumulate advanced glycation Amadori end products which affect binding of regulatory molecules, susceptibility to proteolysis and finally decrease the ability for protein cross-linkage¹⁵. Di Girolamo *et al.*¹⁶ postulated that defects in wound healing are caused by the hyperglycosylation of the locally synthesized cellular fibronectin. However hyperglycaemia affects the whole range of neutrophil functions, which include migration, chemotaxis, adherence, and phagocytic and bactericidal activity¹⁷.

Carica papaya extract showed wound healing properties after its topical application in streptozotocin-induced diabetic rats. The wound size reduced as early as Day 5 in animals with induced diabetes compared with wounds in the control animals and those that were treated with topical mupirocin. The observed increase in hydroxyproline, a specific marker of collagen and an important component of extracellular granulation tissue matrix in the wounds treated with *C. papaya* clearly indicated rapid collagen turnover and accumulation, explaining the increased rate of wound contraction. Starley *et al.*¹⁸ reported that application of the fruit pulp to full thickness and infected pediatric burns provided effective desloughing of necrotic tissue and sufficient wound granulation which was suitable for a split thickness skin graft. They suggested that the

proteolytic enzyme activity and antimicrobial activity of chymopapain and papain may explain healing of burn wounds. Proliferation of both wet and dry granulation tissue in diabetic rats after *C. papaya* extract application was significantly higher even in comparison with wounds treated with mupirocin. These findings have particular application to promote wound healing in diabetes and merit further investigation. The wound healing property of *C. papaya* in burns has been attributed to its antibacterial effect^{18,19} but we are not aware of reports of its proliferative effect on granulation tissue.

The absence of a biofilm was singularly observed in diabetic animals that were treated with the fruit preparation. This suggests that enzyme constituents of *C. papaya* breakdown the biofilm defences which protect against UV light and oxygenation and promote a bacterial imbalance. Due to increasing evidence that bacteria in wounds with potential chronicity live within biofilm communities, protecting them from host defences, the study of biofilms has become an area of intense scientific investigation in wound healing and bacterial resistance²⁰, both of which are relevant to the diabetic state.

The concept of using proteolytic enzymes as adjunctive management of “dirty”, infected wounds most likely relates to the practices of natives in tropical countries, who used papain-rich latex of *C. papaya*, (obtained by scratching the skin of the green fruit), to treat eczema, warts, ulcers, and varied types of sores²¹. Papain, the active component of

C. papaya offers enzymatic debridement of wounds besides being rich in vitamin C which is essential in the conversion of proline to hydroxyproline. The antimicrobial activity of *C. papaya* has most likely contributed to its wound healing effect following breakdown of the wound biofilm.

The present study demonstrates that *C. papaya* extract applied topically promotes healing of wounds, with enhanced rate of collagen turnover and wound contraction in streptozotocin induced diabetic rats where healing is delayed. These preliminary results further suggest that *C. papaya* facilitates healing by increasing the rate and extent of wound closure and hydroxyproline content in wounds subject to delayed healing.

Acknowledgement

The study was supported by a grant from the Caribbean Health Research Council, Trinidad. The authors thank Mrs. Yasmin S for identifying and depositing the specimen at the National Herbarium, Trinidad and Tobago, and the chief microbiology technician, Sanferando Government Hospital, Trinidad and Tobago for technical assistance.

References

- 1 Falanga V, The Chronic wound: Impaired wound healing and solutions in the context of wound bed preparation, *Blood Cells Mol Dis*, 32 (2004) 88.
- 2 Singer A J & Clark R A, Cutaneous wound healing, *N Engl J Med*, 341 (1999) 738.
- 3 Goodson W H & Hunt T K, Studies of wound healing in experimental diabetes Mellitus, *J Surg Res*, 22 (1977) 221.
- 4 Chen C F, Chen S M, Chow S Y & Han P W, Protective effects of *Carica Papaya* Linn on the exogenous gastric ulcer in rats, *Am J Chinese Med*, 9 (1981) 205.
- 5 Emeruwa A, Antibacterial substance from *Carica Papaya* fruit extract, *J Natural Prod*, 45 (1982) 132.
- 6 Rimbach G, Guo Q, Akiyama T, Matsugo S, Moini H, Virgili F & Packer L, Ferric nitrilo triacetate induced DNA and protein damage: Inhibitory effect of a fermented *papaya* preparation, *Anticancer Res*, 20 (2000) 2907.
- 7 Gupta O P, Sing S, Bani S, Sharma N, Malhotra S, Gupta B D, Banerjee S K & Handa S S, Anti-inflammatory and anti-arthritis activities of silymarinacting through inhibition of 5-lipoxygenase, *Phytomedicine*, 7 (2000) 21.
- 8 Dawkins G, Hewitt H, Wint Y, Obiefuna P C & Wint B, Antibacterial effects of *Carica papaya* fruit on common wound organisms, *West Indian Med J*, 52 (2003) 290.
- 9 Mahmood A A, Sidik & Salmah I, Wound Healing Activity of *Carica papaya* L. Aqueous Leaf Extract in Rats., *Int J Molecular Med Ad Sci*, 1 (2005) 398.
- 10 Jalalpure S S, Patil M B, Prakash N S, Hemalatha K & Manvi F V, Hepatoprotective activity of fruits of *Piper longum* L., *Indian J Pharm Sci*, 65 (2003) 363.
- 11 Morton J J P & Malone M H, Evaluation of vulnerary activity by an open wound procedure in rats, *Arch Int Pharmacodyn*, 196 (1972) 117.
- 12 Turner R A, Inflammatory agent in screening methods of pharmacology, 2nd ed. (Academic Press, New York) 1965.
- 13 Neuman R E & Logan M A, The determination of hydroxyproline, *J Biol Chem*, 184 (1950) 299.
- 14 Greenhalgh D G, Wound healing and diabetes mellitus, *Clinics Plastic Surg*, 30 (2003) 37.
- 15 Reiser K M, Nonenzymatic glycation of collagen in aging and diabetes, *Proceedings for the Society of Experimental Biology and Medicine*, 218 (1998) 23.
- 16 Di Girolamo N, Underwood A, McCluskey PJ & Wakefield D, Functional activity of plasma fibronectin in patients with diabetes mellitus, *Diabetes*, 42 (1993) 1606.
- 17 Wall S J, Sampson M J, Levell N & Murphy G, Elevated matrix metalloproteinase-2 and -3 production from human diabetic dermal fibroblasts, *Br J Dermatol*, 149 (2003) 13.
- 18 Starley I F, Mohammed P, Schneider G & Bickler S W, The treatment of paediatric burns using topical papaya, *Burns*, 25 (1999) 636.
- 19 Mikhail'chik E V, Ivanova A V, Anurov M V, Titkova S M, Pen'kov L Y, Kharaeva Z F & Korkina L G, Wound-healing effect of papaya-based preparation in experimental thermal trauma, *Bull Exp Biol Med*, 137 (2004) 560.
- 20 Edwards R & Harding KG, Bacteria and wound healing, *Curr Opin Infect Dis*, 17 (2004) 91.
- 21 Sherry S & Fletcher AP, Proteolytic enzymes: a therapeutic evaluation, *Clin Pharmacol Ther*, 1 (1960) 202.